

54 Days Without Anticoagulation in a Patient with Metallic Mitral Valve

Olukolade Owojori and Syed Asher Hussain Zaidi

Doncaster and Bassetlaw Hospitals NHS Foundation Trust, Doncaster, South Yorkshire, UK.

BACKGROUND: In patients with a mechanical heart valve, adequate anticoagulation is extremely important, as coagulation poses a risk of embolism and thrombosis of the valve. However, in patients with a metallic heart valve suffering an intracranial bleed, there is a high mortality rate. This can become a management dilemma, as limited evidence is available to guide clinical decision-making in this situation. Each case must be assessed individually, ideally with a multidisciplinary team approach. Here, we report the case of a woman in her 80s presenting with acute massive subdural hemorrhage because of a fall. We examine the complex repercussions of specific decisions in a very critical clinical scenario. Furthermore, we suggest that a revision of anticoagulation guidelines may be necessary.

KEYWORDS: anticoagulation, metallic heart valve, intracranial bleed, thromboembolism

CITATION: Owojori and Zaidi. 54 Days Without Anticoagulation in a Patient with Metallic Mitral Valve. *Clinical Medicine Insights: Geriatrics* 2015;8 7–10 doi:10.4137/CMGer.S28033.

TYPE: Case Report

RECEIVED: April 28, 2015. **RESUBMITTED:** July 26, 2015. **ACCEPTED FOR PUBLICATION:** July 30, 2015.

ACADEMIC EDITOR: Atsushi Sakuraba, Editor in Chief

PEER REVIEW: Four peer reviewers contributed to the peer review report. Reviewers' reports totaled 1,308 words, excluding any confidential comments to the academic editor.

FUNDING: Authors disclose no funding sources.

COMPETING INTERESTS: Authors disclose no potential conflicts of interest.

COPYRIGHT: © the authors, publisher and licensee Libertas Academica Limited. This is an open-access article distributed under the terms of the Creative Commons CC-BY-NC 3.0 License.

CORRESPONDENCE: mz25@hotmail.com

Paper subject to independent expert blind peer review. All editorial decisions made by independent academic editor. Upon submission manuscript was subject to anti-plagiarism scanning. Prior to publication all authors have given signed confirmation of agreement to article publication and compliance with all applicable ethical and legal requirements, including the accuracy of author and contributor information, disclosure of competing interests and funding sources, compliance with ethical requirements relating to human and animal study participants, and compliance with any copyright requirements of third parties. This journal is a member of the Committee on Publication Ethics (COPE).

Published by Libertas Academica. Learn more about this journal.

Case Presentation

A woman in her 80s was admitted with a head injury caused by a fall. She had been on warfarin for metallic mitral valve (St Jude Medical bileaflet) for the past eight years, with a background of hypertension, hypercholesterolemia, permanent pacemaker for complete heart block, coronary artery bypass graft (CABG × 2), chronic kidney disease, iron deficiency anemia, bilateral total knee replacement, and right total hip replacement. She was diagnosed with acute subdural hematoma (SDH) of 5 mm depth at right cerebral hemisphere on that presentation. Therefore, warfarin and antihypertensives were stopped and low molecular weight heparin (LMWH) was started for two weeks. Admitting international normalized ratio (INR) was not stated; however, prothrombin concentrate (beriplex) was given. The patient was discharged home the same day on LMWH (enoxaparin, 1.5 mg/kg/day) with a view to recommence warfarin in two weeks. The patient was asymptomatic at that time, with only a complaint of mild headache that had resolved. A follow-up with the local hospital was planned.

The patient was readmitted three days later via Accident & Emergency, with severe headache and vomiting and increased confusion with a Glasgow Coma Scale (GCS) score of 9/15. She exhibited stroke-like syndrome, with dense left hemiparesis. The patient started having seizures within 24 hours of admission and phenytoin was commenced. CT scan of the head done on the same day showed extension of right SDH with significant midline shift to the left and compression of the right lateral ventricle

(see Figs. 1–3, including significant acute on chronic SDH picture). INR at that point was 1.1.

The neurosurgeons considered the case to be unsuited for surgery at this point; hence, the guarded prognosis was discussed with the family, and the management plan was devised accordingly. Blood pressure was found to be 212/88, which was initially treated with labetalol and later with glyceryl trinitrate patch 5 mg daily. It was decided to continue withholding anticoagulants for 14 days in the first instance, and then repeat CT scan with the aim of recommencing a half-dose therapeutic LMWH. Depending on CT scan and clinical condition, the plan was to restart warfarin 29 days after the second admission. It was decided to do a daily clotting profile, and a loading dose of IV phenytoin and maintenance doses were given. Other symptomatic management and Do Not Attempt Cardiopulmonary Resuscitation (D-NACPR) forms were done, in liaison with other multidisciplinary teams, eg, neurosurgical, cardiology, and stroke teams, as appropriate. It was decided to have a low threshold to keep the patient comfortable in the event of further deterioration of GCS.

A CT scan of the head was repeated 14 days later, and comparison with the previous examination showed an improvement in the volume of acute hemorrhage (see Fig. 4). There was a small volume of further hemorrhage in the subdural region. The degree of midline shift had not changed. The subtle edema in the right hemisphere noted on the previous examination was no longer apparent, and there were no signs of established territorial infarction. At this point of

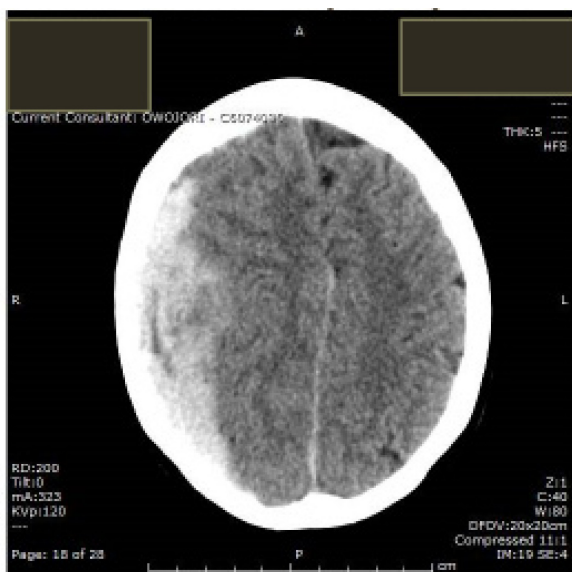


Figure 1. CT Head showing massive subdural hemorrhage with midline shift.

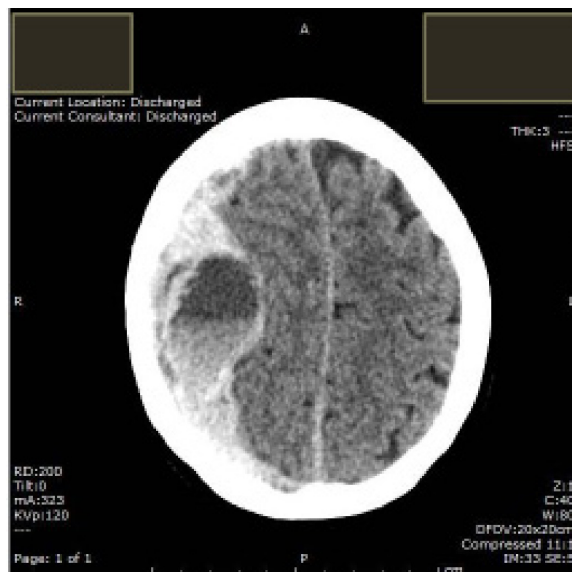


Figure 3. Sequential CT scan Head.

time, the patient’s GCS was 12/15, but she was now having intercurrent infections in the chest and urinary tract, as well as cellulitis.

After reviewing the repeat scans, it was deemed unsuitable for any form of anticoagulation to be restarted. Therefore, after an additional 14 days, a repeat CT scan of the head was done (Fig. 5). At this stage, it had been 28 days since readmission, and a slight reduction in the size of the right SDH was noted, 11 mm deep compared to 15 mm. The amount of acute blood had considerably decreased with minimal high density remaining. The associated edema and minimal midline shift had also decreased, although still present.

At the time of the second follow-up scan, the patient had a GCS 14/15 and was able to eat soft foods and be moved by Rotunda +2 transfer. At this point, Multidisciplinary team (MDT) advice was sought. The neurosurgeons’ response was that the decision about anticoagulation would be guided by cardiology. Advice from the cardiology team members was that ideally, a person with metallic heart valve should be on anticoagulation, but in this case, the decision should be guided by neurosurgery and the patient’s wishes. The patient and her relatives stated in unequivocal terms that they did not want anticoagulation.

CT scan of the head was repeated again on the 54th day and showed an isodense right-sided SDH (Fig. 6).

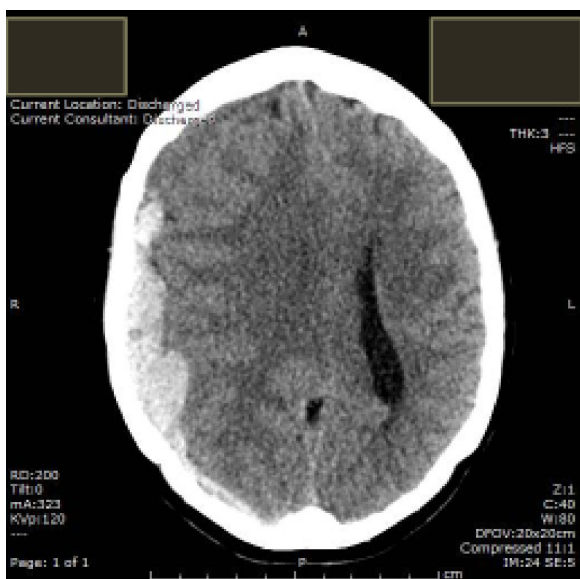


Figure 2. Sequential CT scan Head.

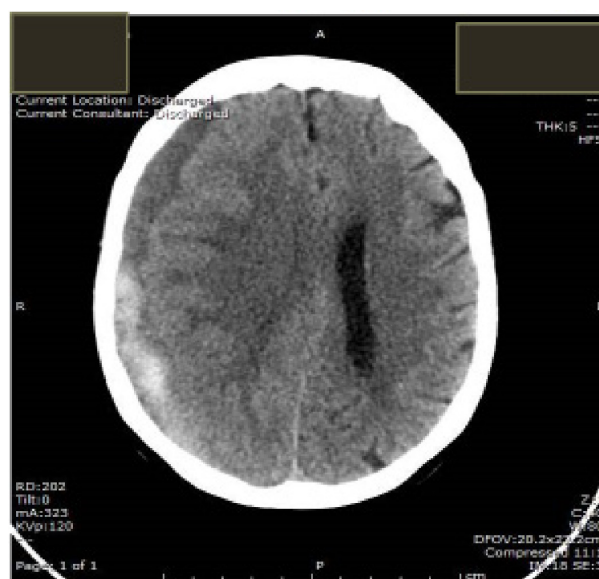

Figure 4. Sequential CT scan Head.

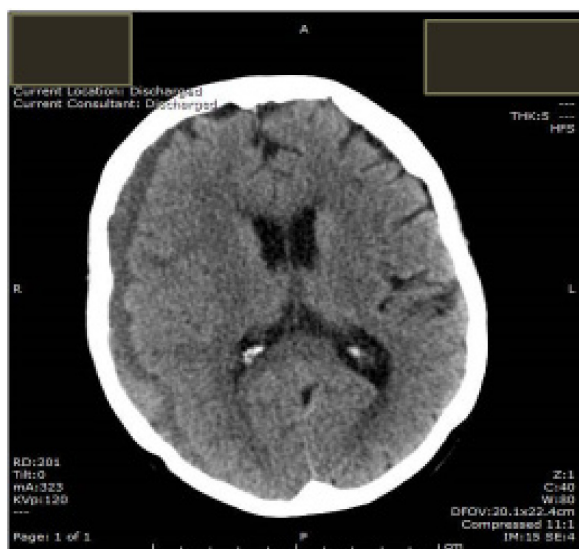


Figure 5. Sequential CT scan Head.

Previously almost 10 mm thick, it was reduced to 6 mm. The patient was now mobile with a frame and on a normal diet. After regular discussions with the patient and all the relevant MDTs regarding the need for anticoagulation, warfarin was commenced on the 55th day after a transesophageal echocardiogram that did not show any clots or valve failure.

On the 57th day of stay in the stroke rehabilitation ward, the patient was deemed medically fit for discharge with INR in the therapeutic range. Instructions were given to the patient and relatives to take extra care that the patient not fall over, and that if she experienced any headaches or drowsy spells, she should be taken to the hospital. Cardiology, stroke team, and neurosurgical follow-up was arranged. She walked out of the hospital on the 57th day.

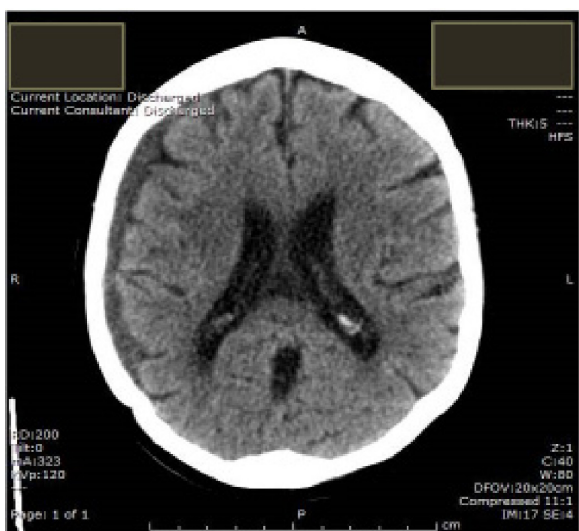


Figure 6. Sequential CT scan Head.

Discussion

It has been reported that a patient with a mechanical aortic valve (Björk–Shiley mechanical heart valve) has lived for 26 years without thromboembolic events. Another patient with a St Jude mitral valve prosthesis survived for 10 years without any thromboembolic event. One of the many studies that looked at the risks of thromboembolism in patients with mechanical heart valves concluded that the incidence of valve thrombosis was 1.7% per year (in the absence of anticoagulation) and that the incidence of major embolism was 4% per year.¹

Of the available tools for detection of valve failure or thrombosis, digital phonocardiography (DP) is particularly useful to detect mechanical valve thrombosis in a very early stage.² It can be used for daily surveillance of mechanical heart valves, especially after discontinuation of anticoagulation. It is a real-time noninvasive method to evaluate the sound of the valve opening and closing within a frequency range between 8 and 22 kHz, and it measures the acoustic energy, resonance frequency, and the time interval between leaflet movements. Thus, DP records an individual electronic fingerprint of each patient. Using DP, a diagnosis could be made and the indication for operation established. DP can be undertaken by the patients themselves and is superior to echocardiogram and fluoroscopy.

Patients with mechanical mitral valves have a fivefold increase in the risk of valve thrombosis and 1.5-fold increase in the risk of major embolism when compared with those of mechanical aortic valves. Aspirin reduces the risk of valve thrombosis from 1.7% to 1.0%. Anticoagulation reduces it further to 0.2%. Some studies say that the risk of recurrent bleeding is 2%–3% per year without antiplatelet or anticoagulant therapy. This corresponds to an increase in relative risk over the general population of ~10-fold with anticoagulation.³

The site of the initial hemorrhage is also important, as lobar hemorrhage involving the cerebral cortex appears to carry a higher risk of recurrence than deep hemispheric hemorrhage. According to recent literature, stopping anticoagulant therapy in patients who have intracranial bleeds with mechanical heart valve for 7–14 days was found to be safe.⁴ The European Stroke Initiative states the above and recommends anticoagulation to be recommenced within 10–14 days in such patients, whereas the American Heart Association recommends restarting anticoagulants within 7–10 days.⁵ Recent French guidelines suggest restarting anticoagulation in such patients in 48–72 hours for large extracranial bleeds and one to two weeks for intracranial bleeds.⁶ This applies to both traumatic and spontaneous bleeds in the context of a mechanical heart valve. Overall, it can be concluded that management of warfarin-induced major bleeding in patients with mechanical heart valves is challenging and needs to be tailored to different patients according to the clinical picture supported by relevant imaging at different stages. Hence, we believe that there can be no specific guidelines set to manage it in a better way.



Author Contributions

Conceived and designed the experiments: OO and SAHZ. Analyzed the data: OO and SAHZ. Wrote the first draft of the manuscript: OO and SAHZ. Contributed to the writing of the manuscript: OO and SAHZ. Agree with manuscript results and conclusions: OO and SAHZ. Jointly developed the structure and arguments for the paper: OO and SAHZ. Made critical revisions and approved final version: OO and SAHZ. Both authors reviewed and approved of the final manuscript.

REFERENCES

1. Yildiz A, Ozcan F, Dogan M, Ozlu MF, Samaaz A. Twenty-two years without anticoagulation with metallic heart valve. *J Natl Med Assoc.* 2006;98(8):1348–1349.
2. Fritzsche D, Eitz T, Laczkovics A, et al. Early detection of mechanical valve dysfunction using a new home monitoring device. *Ann Thorac Surg.* 2007;83(2):542–548.
3. Claassen DO, Kazemi N, Zubkov AY, Wijdicks EF, Rabinstein AA. Restarting anticoagulation therapy after warfarin-associated intracerebral hemorrhage. *Arch Neurol.* 2008;65:1313–1318.
4. Sjöblom L, Hårdemark HG, Lindgren A, et al. Management and prognostic features of intracerebral haemorrhage during anticoagulant therapy: a Swedish multicentre study. *Stroke.* 2001;32(11):2567–2574.
5. Morgenstern LB, Hemphill JC 3rd, Anderson C, et al; American Heart Association Stroke Council and Council on Cardiovascular Nursing. Guidelines for the management of spontaneous intracerebral hemorrhage: a guideline for healthcare professionals from the American Heart Association/American Stroke Association. *Stroke.* 2010;41:2108–2129.
6. Pernod G, Godiér A, Gozalo C, Tremey B, Sié P. French clinical practice guidelines on the management of patients on vitamin K antagonists in at-risk situations (overdose, risk of bleeding, and active bleeding). *Thromb Res.* 2010;126:e167–e174.