

# Paraneoplastic Manifestations of Lymphoproliferative Neoplasms

Pavankumar Tandra<sup>1</sup>, Avyakta Kallam<sup>1</sup>, Mounika Guduru<sup>2</sup>, Venkata Sunil Bendi<sup>2</sup>,  
Jairam Krishnamurthy<sup>3</sup> and Philip Bierman<sup>1</sup>

<sup>1</sup>Hematology-Oncology Division, Internal Medicine Department, University of Nebraska Medical Center, Omaha, NE, USA. <sup>2</sup>Shenandoah Medical Center, Shenandoah, IA, USA. <sup>3</sup>Oncology Division, Medical Oncology Section, Washington University Medical School, St. Louis, MO, USA.

**ABSTRACT:** Paraneoplastic syndromes, although rare, have been associated with lymphoproliferative disorders. Hodgkin's lymphoma (HL) is the most common lymphoid neoplasm known to cause paraneoplastic syndromes. These syndromes can often be the earliest manifestation of the underlying malignancy, and treating the underlying lymphoma can cure the paraneoplastic disease. Paraneoplastic diseases reported in lymphoid malignancies can be broadly classified into hematological, neurological, and dermatological syndromes based on the organ systems that are predominantly involved. In addition, renal and hepatobiliary involvement has also been reported. The pathogenesis of the hematological paraneoplastic conditions primarily involves the production of autoantibodies by the neoplastic lymphocytes, which then subsequently leads to cytopenias. Cytoses are a result of cytokine produced by the neoplasms. The administration of corticosteroids along with chemotherapy for the underlying malignancy is the treatment of choice. Neurological paraneoplastic phenomena have been reported in both HL and non-Hodgkin's lymphoma (NHL). They are thought to be secondary to an immune-related process that is triggered by the underlying process. Both the central and the peripheral nervous systems can be affected. Often, treatment of the underlying malignancy with chemotherapy can result in reversal of the paraneoplastic syndrome. In peripheral neuropathies, muscle relaxants and analgesics are often used for symptomatic relief. Dermatological manifestations, pemphigus vulgaris in particular, often precedes the malignancy. Renal and hepatobiliary manifestations, although rare, are also associated with lymphomas.

**KEYWORDS:** lymphoproliferative neoplasms, paraneoplastic, lymphoma, neurological manifestations of lymphoma, hematological manifestations of lymphoma

**CITATION:** Tandra et al. Paraneoplastic Manifestations of Lymphoproliferative Neoplasms. *Lymphoma and Chronic Lymphocytic Leukemias* 2016;6:21–33 doi:10.4137/LCLL.S38507.

**TYPE:** Review

**RECEIVED:** January 4, 2016. **RESUBMITTED:** April 5, 2016. **ACCEPTED FOR PUBLICATION:** April 12, 2016.

**ACADEMIC EDITOR:** Mitchell Smith, Editor in Chief

**PEER REVIEW:** Four peer reviewers contributed to the peer review report. Reviewers' reports totaled 867 words, excluding any confidential comments to the academic editor.

**FUNDING:** Authors disclose no external funding sources.

**COMPETING INTERESTS:** Authors disclose no potential conflicts of interest.

**COPYRIGHT:** © the authors, publisher and licensee Libertas Academica Limited. This is an open-access article distributed under the terms of the Creative Commons CC-BY-NC 3.0 License.

**CORRESPONDENCE:** pav.tandra@unmc.edu

Paper subject to independent expert single-blind peer review. All editorial decisions made by independent academic editor. Upon submission manuscript was subject to anti-plagiarism scanning. Prior to publication all authors have given signed confirmation of agreement to article publication and compliance with all applicable ethical and legal requirements, including the accuracy of author and contributor information, disclosure of competing interests and funding sources, compliance with ethical requirements relating to human and animal study participants, and compliance with any copyright requirements of third parties. This journal is a member of the Committee on Publication Ethics (COPE).

Provenance: the authors were invited to submit this paper.

Published by Libertas Academica. Learn more about this journal.

## Introduction

The term *paraneoplastic syndrome* refers to the clinical manifestations that are not directly related to the tumor burden, tumor invasion, or metastases, but are caused by the secretion of tumor cell products such as hormones, growth factors, cytokines, and tumor antigens.<sup>1</sup> These are rare in lymphoid neoplasms. Hodgkin's lymphoma (HL) is the most common lymphoma associated with a variety of paraneoplastic phenomena affecting multiple organ systems.

Paraneoplastic syndromes may present at the diagnosis, develop later in the course of the disease, or at the relapse of the lymphoma. Treating the underlying lymphoma cures the paraneoplastic disease in many cases. However, some patients may need immunosuppressive therapy.

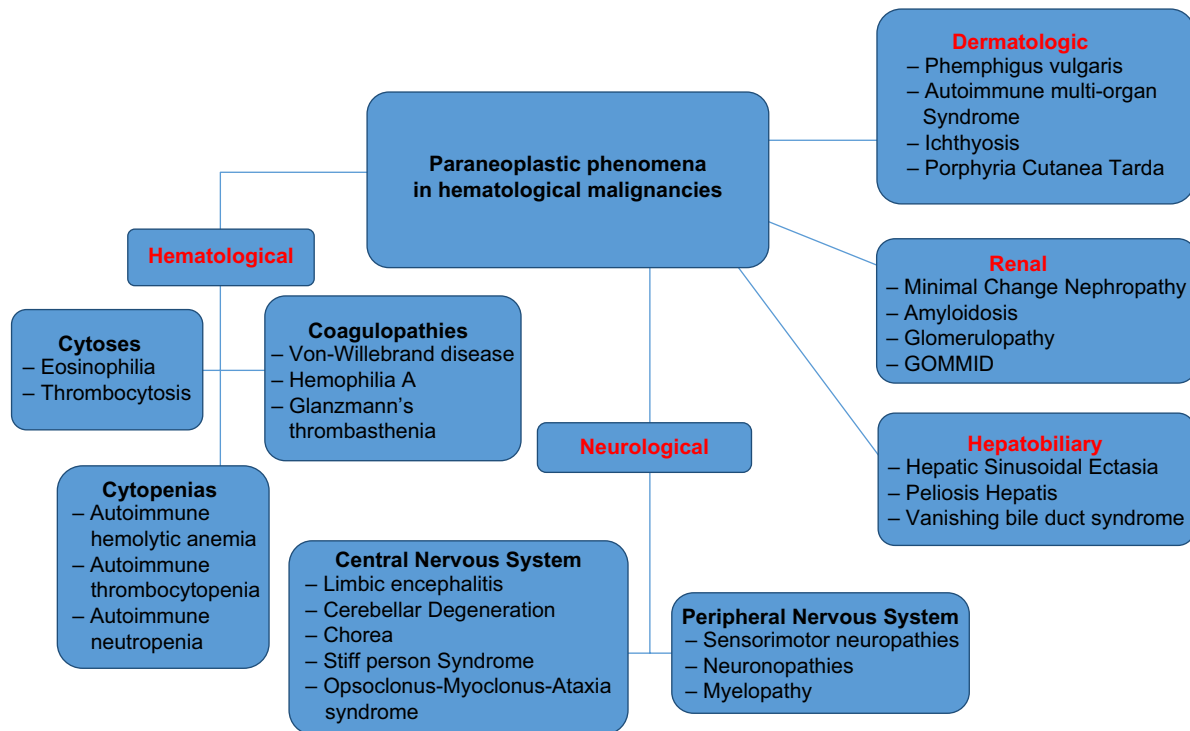
In this review, we discuss various paraneoplastic syndromes associated with lymphoid neoplasms, pathogenesis, clinical features, diagnosis, and their management Figure 1.

## Hematological Paraneoplastic Phenomena

**Autoimmune cytopenias.** The most common hematologic paraneoplastic phenomena in lymphomas are autoimmune

hemolytic anemia (AIHA) and autoimmune thrombocytopenia (AITP). Autoimmune neutropenia (AIN) is rare. Chronic lymphocytic leukemia (CLL) is the most common lymphoproliferative disorder associated with autoimmune cytopenias. Non-Hodgkin's lymphoma (NHL) and HL can also cause cytopenias.

The pathogenesis of autoimmune cytopenias involves the production of autoantibodies to the erythrocytes and platelets by the neoplastic and non-neoplastic lymphocytes.<sup>2,3</sup> In AIHA, the production of autoantibodies results from both T-lymphocyte dysfunction and malignant B lymphocytes. Malignant B lymphocytes act as antigen-presenting cells and introduce the antigen to the T-helper cells, leading to their activation. The activated T-helper cells mediate antibody production by the B lymphocytes. The Rh antigens on the surface of the red blood cells produce these antibodies and destroy the red blood cells.<sup>4,5</sup> In CLL, nonmalignant B-cells produce 90% of autoantibodies rather than malignant B-cells.<sup>6</sup> Platelet surface glycoprotein antigens Ib/IX and IIb/IIIa produce these antibodies.<sup>7,8</sup> These are polyclonal and immunoglobulin subtype G (IgG) in nature. In 10% of cases, the mechanism



**Figure 1.** Various paraneoplastic phenomena seen in hematological malignancies.

**Abbreviation:** GOMMID, Glomerulonephritis with organized microtubular monoclonal Ig deposits (Immunotactoid glomerulonephritis).

is similar to cold hemagglutinin disease, where the malignant B-cells produce monoclonal antibodies of IgM subtype.<sup>9</sup> There is evidence to suggest that the suppression of Treg cells also leads to autoimmunity in CLL, especially in fludarabine-related autoimmunity.<sup>7,8,10,11</sup>

AIN is extremely rare and is often a diagnosis of exclusion. The pathogenesis of AIN is not well studied. One of the proposed mechanisms is the production of antineutrophil antibodies leading to agglutination of neutrophils, phagocytosis, and complement-mediated neutrophil destruction.<sup>12,13</sup> Large granular lymphocytic leukemia, hairy cell leukemia, and HL can cause AIN. In CLL, fludarabine, rituximab, and alemtuzumab have also been associated with AIN.<sup>14,15</sup>

Warm AIHA is more common than cold AIHA (cold agglutinin disease). AIHA is more common in NHL than in HL. AIHA has an incidence of 3%–5%<sup>16</sup> in NHL and 0.2%–2% in HL.<sup>17</sup> In one report,<sup>17</sup> seven out of 71 patients with HL had positive direct Coombs test, and all of them had advanced stage (stages III and IV) disease. Although all of them have anemia, only three of them have clear evidence of overt hemolysis. Three patients have the antibody responsible (IgG anti-It) for Coombs positive hemolysis.

In contrast to AIHA, AITP appears to be more common in HL compared to NHL. The incidence of AITP has been estimated to be 1%–2%.<sup>18</sup> AITP presents with thrombocytopenia unrelated to the underlying lymphoproliferative disorder. It is usually a diagnosis of exclusion. Isolated thrombocytopenia without anemia is more likely to be autoimmune in

origin.<sup>19,20</sup> Demonstration of increased bone marrow response to thrombocytopenia by the production of megakaryocytes confirms the diagnosis. Bone marrow biopsy shows normal or increased megakaryocytes with immature forms. Response to the trial of an intravenous immunoglobulin (IVIg) or corticosteroids can confirm the diagnosis if the bone marrow is inconclusive. Thirty percent of cases of AITP also have simultaneous AIHA (Evans syndrome).<sup>21,22</sup>

In contrast, AIN is extremely rare and difficult to diagnose with certainty.<sup>12,13</sup> It is a diagnosis of exclusion, and it should be suspected when there is persistent and prolonged absolute neutropenia, and bone marrow examination demonstrates a failure of the neutrophil production or maturation arrest.<sup>23</sup>

Therapy of autoimmune cytopenias should include treatment for the underlying lymphoproliferative disorder as well as specific measures for the treatment of cytopenias. It may involve replacement of packed red cells and platelets in case of an emergency. IVIG and nonphysiologic doses of steroids are alternative treatment strategies. The mechanism of IVIG in improving the cytopenias is unknown. The B-cell mediated effects of IVIG such as inhibition of antibody production, inhibition of B-cell differentiation, and induction of B-cell apoptosis may play a role (Table 1).

**Eosinophilia and thrombocytosis.** Paraneoplastic eosinophilia and tissue eosinophilia are reported in lymphoproliferative disorders, most commonly in HL and T-cell lymphomas. There are also reports of eosinophilic infiltration of skin (eosinophilic fasciitis), lung, and gastrointestinal tract.

**Table 1.** Rare Hematological paraneoplastic phenomena reported in the literature.

REFERENCE	PN SYNDROME	NO.	ASSOCIATION	OTHER FEATURES
(149)	AIHA	2	HL	Minimum tumor load of HL was undetected and one patient died and diagnosis was found at autopsy
(150)	Cyclic AIHA	1	Splenic HL	Splenectomy resolved AIHA
(151)	Transient bone marrow Aplasia	1	HL	Reversed with combination chemotherapy
(152)	Positive coombs test	7/71	HL	Associated with antibody IgG anti-Ig
(153, 154)	Microcytic anemia	1	HL	2 case reports & review of 162 patients. IDA and B-Thalasemia most common
(155)	Deficiency of coagulation factors VII and XII	1	HL	
(156)	Hypo fibrinogenemia	1	HL	
(157)	Fibrinolysis and proteolysis	1	Lymphoma	
(158)	Acquired Factor VIII inhibitor deficiency	1	Lymphoma	
(152)	Positive coombs test	1	HL	
(153, 154)	Microcytic anemia	1	HL	

**Abbreviations:** AIHA, Auto Immune Hemolytic Anemia; HL, Hodgkins Lymphoma; IDA, Iron Deficiency Anemia.

IL-5 appears to play a significant role in the eosinophilic disorders.<sup>18</sup> Patients with HL are reported to have high eosinophil counts and serum IgE compared to age- and sex-matched controls.<sup>24</sup> Fludarabine and cladribine,<sup>25–27</sup> the drugs used in the treatment of CLL, can also cause eosinophilia.

Sixteen percent of patients with NHL and 21%–24% of patients with HL can present with thrombocytosis.<sup>28</sup> Although the underlying mechanism is unclear, it has been hypothesized that several tumor-derived cytokines, particularly interleukin 6 (IL 6), IL 1, and IL 3 could be responsible for thrombocytosis.<sup>29</sup>

**Coagulopathies.** Coagulopathies in lymphoproliferative disorders include inhibitors of coagulation factors. These usually include either specific inhibitors of the individual coagulation factors or global inhibitors of the coagulation system such as antiphospholipid antibodies.

Several case reports in the literature suggest acquired inhibitors of factor VIII (acquired hemophilia),<sup>30</sup> Von Willebrand factor,<sup>31,32</sup> and glycoprotein IIb/IIIa (Glanzmann's thrombasthenia) in lymphoproliferative diseases. Antiphospholipid antibodies are present in up to 26.6% (24 of 90) of NHL patients. None of the patients in this study developed thrombosis related to antiphospholipid antibodies.<sup>33</sup>

## Neurological Paraneoplastic Phenomena

Paraneoplastic disorders of the nervous system are thought to be secondary to an immune-related process triggered by the underlying lymphoproliferative disorder. The neurons are the targeted antigens. The identification of these antineuronal or onconeural antibodies has revolutionized the understanding of these diseases.

### Central nervous system paraneoplastic disorders.

*Paraneoplastic limbic encephalitis.* Paraneoplastic limbic encephalitis (PLE) is very rare. It is characterized clinically by

personality changes such as irritability, memory loss, depression, and, sometimes frank psychosis. Temporal lobe involvement causes generalized or complex partial seizures in up to 50% of the patients.<sup>34</sup> The symptoms usually precede the diagnosis of the lymphoma.

In a report by Gultekin et al, the diagnosis of the PLE requires either pathological confirmation or presence of four clinical criteria.<sup>34</sup> The clinical criteria include a compatible clinical picture, an interval of fewer than four years between the neurological symptoms and the diagnosis of the tumor, an exclusion of the other neuro-oncological complications, and one of the following laboratory findings. Negative cytology with evidence of inflammation in the cerebrospinal fluid (CSF), temporal lobe abnormalities on magnetic resonance imaging (MRI), and epileptic activity in the temporal lobes on the electroencephalogram (EEG). In this series, HL is the fourth most frequent (4%) association with PLE after lung (50%), germ cell tumors (20%), and breast cancer (8%). Lymphoma has no identified specific onconeural antibodies in this report.

The association of the PLE with HL is known as Ophelia syndrome. Dr. Carr described an insidious neuropsychiatric degeneration in his 15-year-old daughter who suffered from HL.<sup>35</sup> Antibodies against mGLUR5 (metabotropic glutamate receptor 5) are present in Ophelia syndrome.<sup>36,37</sup> Lymphoma also causes an acute severe diffuse paraneoplastic encephalitis.<sup>38</sup> In one such case report, treatment with Adriamycin, Bleomycin, Vinblastine, and Dacarbazine (ABVD) dramatically improved mental status in a patient of HL suggesting a paraneoplastic phenomenon.

The diagnosis of PLE requires clinicopathological, neuroradiological, EEG, and CSF confirmation as recommended by Gultekin et al as abovementioned. It is important to apply this criterion to avoid misdiagnosis of PLE among patients presenting with similar symptoms.



The treatment of PLE involves treating the HL. The prognosis is good, and the treatment often leads to full recovery<sup>36,37</sup> because it is due to reversible neuronal dysfunction caused by the pathogenic mGluR5 antibody rather than neuronal death.<sup>39</sup>

PLE is exceedingly rare in NHL.<sup>39</sup> In two cases of renal NHL presenting as PLE, removal of the primary renal lymphoma in one patient<sup>40</sup> and treatment with rituximab, cyclophosphamide, adriamycin, vincristine, and prednisone (R-CHOP) and intrathecal methotrexate in the other patient led to complete neurological remission.<sup>41</sup> In another case report, the patient presented with a transformed NHL and PLE with pathognomic MRI features and treatment with chemotherapy resulted in a full neurological recovery.<sup>42</sup> None of these NHL patients has pathogenic onconeural antibodies.

*Paraneoplastic cerebellar degeneration.* Paraneoplastic cerebellar degeneration (PCD) is common in lung and breast cancer. However, HL can also cause PCD.<sup>43</sup> The pathological hallmark of PCD is a severe loss of cerebellar Purkinje cells resulting in a subacute pan cerebellar dysfunction. This pattern is distinct from that of PCD with gynecologic cancer (associated with anti-Yo) or small-cell lung cancer (SCLC) (associated with anti-Hu).<sup>44</sup>

PCD antedates the diagnosis of HL in ~80% of the cases.<sup>45</sup> It can also develop after the diagnosis of HL is established or during remission.<sup>44</sup> Dizziness, vomiting, and vertigo are the initial symptoms. They can also present with dysarthria, diplopia, and downbeat nystagmus. These symptoms can rapidly progress to severe symmetrical truncal and limb ataxia. CSF examination is not diagnostic and shows moderate pleocytosis.

MRI studies usually show cerebellar atrophy. Trotter et al first detected the pathognomic antibodies (Tr antibodies),<sup>46</sup> and these can be found both in the serum and CSF. DNER (Delta/Notch-like epidermal growth factor-related receptor) is the antigen for the Tr antibody.<sup>47,48</sup> Purkinje cell dendrites preferentially express these DNER transmembrane antigens. Unlike other paraneoplastic antigens, they have not been identified in tissue samples of HL. It suggests that the ectopic secretion of the antigen does not trigger the immune responses.<sup>39</sup> Two patients with HL, after a few years of their diagnosis, present with PCD related to a different antibody, mGluR1 (metabotropic glutamate receptor type 1). However, subsequent reports have not confirmed this association.<sup>49,50</sup>

Treatment of PCD involves treating the underlying HL. PCD associated with DNER Ag (in HL) does not respond as well when compared to the PCD related to other cell membrane antigens in other tumors.<sup>51</sup> Two large case series about the treatment of PCD in HL were published in the literature.<sup>44,45</sup> In one series of 21 patients, neither plasmapheresis (7 of 21) nor immunosuppressive agents including steroids (8 of 21) were helpful. Spontaneous resolution was reported (2 of 21), and improvement with clonazepam helped one patient. Also, seropositive patients did not differ clinically from seronegative patients. When these two reports were combined (a total of

49 patients), 7 (14%) had full or partial neurological recovery and the Tr (to DNER Ag) antibody titers usually disappear after treatment of the HL.

*Paraneoplastic chorea.* A chorea is a form of dyskinesia defined as brief, abrupt, irregular, unpredictable, and nonstereotyped movements.<sup>52</sup> In milder cases, they may appear purposeful, affect various body parts, and interfere with speech, swallowing, posture, and gait. In contrast, athetosis is a more distal, slower, writhing, and abnormal movements. In a more severe form called ballism, choreiform movements appear wild and violent and may involve flinging of a body part, causing injuries. MRI brain may show the hyperintensity of caudate nuclei and putamen.

Paraneoplastic chorea (PC) is very rare. In the PNS EuroNetwork experience, only five cases of PC (four due to NHL and one due to HL) secondary to lymphomas have been reported.<sup>53</sup> PC is associated with CV2/Collapsin response mediator protein 5 (CRMP5) antibodies regardless of the tumor association. Finding these antibodies, when present, is a very helpful diagnostic clue,<sup>54</sup> as up to 50% of the patients may not have any onconeural antibodies. The treatment of PC involves immunotherapy and treating the underlying lymphoma; however, a complete remission is rarely achieved.

*Paraneoplastic stiff-person syndrome.* Paraneoplastic stiff-person syndrome (PSPS) is a very rare central nervous system (CNS) paraneoplastic disorder characterized by progressive rigidity and spasms of the axial musculature leading to deformities. Electrophysiology studies reveal continuous co-contraction of the agonist and antagonist muscles, caused by the involuntary and continuous firing of the motor unit potentials at rest. Less than 1% of patients with this disease have an underlying malignancy.<sup>55</sup> Glutamic acid decarboxylase (GAD) antibodies are usually present in PSPS.<sup>56</sup>

A related disorder, progressive encephalomyelitis with rigidity and myoclonus (PERM) causes stiffness and stimulus-sensitive spasms of the muscles leading to brain stem dysfunction. The pathology reveals perivascular lymphocyte cuffing and loss of neurons in the brain stem. Glycine receptor antibodies may be present in some patients with this disease.<sup>57</sup> In five case reports of PERM published in the literature, none of the patients have pathogenic antibodies, and all of them recovered neurologically after their HL was treated successfully.<sup>58-61</sup> Treatment is usually conservative with skeletal muscle relaxants such as Baclofen or benzodiazepines.

*Paraneoplastic granulomatous angiitis.* Paraneoplastic granulomatous angiitis (PGA) of the CNS is a rare cause of neurological deterioration in lymphomas. It is a difficult diagnosis to make and often diagnosed posthumously.

It is characterized histologically by necrotizing inflammation of the walls of small arteries and veins with deposition of noninfectious granulomas composed of lymphocytes, monocytes, and plasma cells.<sup>62</sup> In the CNS, leptomeningeal vessels are usually affected. Although the herpes virus may be a possible etiology for PGA in some cases, viral particles





are not found in the affected blood vessels, supporting an autoimmune mechanism.<sup>63</sup>

Clinically, patients usually complain of headaches, altered mental status, cognitive decline, and focal neurological symptoms. CSF reveals pleocytosis with lymphocytosis, and MRI shows bilateral leukoencephalopathy and perivascular gadolinium-enhancing lesions.<sup>64</sup> HL is the frequent association with PGA. A review of the literature revealed 12 cases of PGA with HL. They usually have a poor prognosis. In one report, six patients were treated aggressively for both angitis and HL. Three patients recovered fully, two had a partial recovery, and one died.<sup>65</sup> Studies have shown associations with Sjögren's syndrome, human immunodeficiency virus infection, and herpes zoster virus (HZV) infection. Therefore, these should be considered in the differential diagnosis.

*Paraneoplastic opsoclonus-myoclonus-ataxia syndrome.* Opsoclonus-myoclonus-ataxia syndrome (OMAS) is characterized by irregular, chaotic, large amplitude conjugate saccades in all directions of gaze and diffuse myoclonus.<sup>66</sup> Myoclonus often involves the trunk, head, limbs, and facial muscles causing truncal ataxia, dysarthria, and in some, confusion and coma.

OMAS can result from a wide variety of reasons that include infectious and idiopathic causes apart from the paraneoplastic syndromes. Neuroblastoma in children and breast, gynecological, and SCLC in adults are the tumors usually associated with PMAS. Several case reports<sup>67</sup> have suggested an association with lymphomas. Out of these, two of the cases may be secondary to direct effects of the intracranial tumor itself and cannot be considered paraneoplastic.<sup>67,68</sup> In one report,<sup>69</sup> symptoms developed seven weeks after an autologous hematopoietic stem cell transplantation for a relapsed HL and a postinfectious etiology could have been possible. Anti-Ri antibodies characterize breast and gynecological cancers with OMAS, but none is present in lymphomas.

*Peripheral nervous system (PNS) paraneoplastic disorders.* Peripheral neuropathy related to lymphomas has a broad differential diagnosis.<sup>70</sup> Infections such as HZV, chemotherapeutic drugs (vinca alkaloids), direct damage to the neuron bodies (neuronopathy), compression or infiltration of nerves by the lymphoma (lymphomatosis), and radiation-related neuropathy are the usual differential diagnoses. Vasculitis of the vas-nervorum, inflammation, and demyelination are the other causes. Demyelination can be acute (Gullian Barre Syndrome [GBS]) or chronic (chronic inflammatory demyelinating polyradiculopathy [CIDP]).

*Paraneoplastic sensorimotor neuropathy.* Both HL and NHL can present with paraneoplastic sensorimotor neuropathies. In one case series, the authors identified four subgroups based on the pathophysiology of the underlying neuropathy in NHL.<sup>71</sup> These include neurolymphomatosis, autoimmune neuropathy caused by monoclonal IgM with anti-myelin activity, inflammatory or demyelinating neuropathy, and a group in whom the peripheral neuropathy is almost certainly related to the

NHL (likely a paraneoplastic process). In another report<sup>72</sup> evaluating the clinicopathological features of neuropathy in lymphoma, 15 of 32 patients have neurolymphomatosis, and only five patients have paraneoplastic neuropathy.

The demyelinating neuropathies in lymphoma fulfill the criteria of either acute (GBS) or chronic (CIDP) inflammatory demyelinating polyneuropathies. Anti-neuronal antibodies are negative in these patients. Both HL<sup>73-75</sup> and NHL<sup>76-79</sup> can cause paraneoplastic GBS. Neurolymphomatosis are asymmetric or show a pattern of multifocal mononeuropathy like CIDP and respond to steroids. They are distinguished from CIDP by the demonstration of malignant cells in the nerve biopsy or more rarely in the CSF.

*Paraneoplastic neuronopathy.* Clinical manifestations that occur due to direct damage to the cell bodies of the neurons are called neuronopathy. They can affect a particular neuronal type causing a pure motor, sensory, and autonomic or can affect multiple cell types leading to a mixed neuronopathy. They are associated mostly with SCLC in association with anti-Hu antibodies. They are rare in lymphomas and have been reported predominantly in association with HL.

*Pure motor neuronopathy.* Patients with this disorder report weakness of the legs and proximal muscles. HL is almost always the underlying lymphoma. In 1979, the first report of a subacute motor neuronopathy was published in 10 HL patients.<sup>80</sup> It is rarely severe and in some patients, it improves without any treatment. Sometimes, they need IVIG and chemotherapy.<sup>81</sup> It can present at the time of diagnosis or while the disease is in remission. Although an irreversible loss of spinal cord anterior horn neurons may be the underlying pathophysiology, clinical improvement in some patients suggest that other mechanisms such as reversible loss of function of the neurons may play a role.<sup>81</sup>

*Pure sensory neuronopathy.* It is one of the most common neuronopathies caused by damage to the neuron bodies in the dorsal root ganglia. Patients present with subacute pain and paresthesia in the extremities. The sensory loss is asymmetrical and proximal (neck and trunk), and severe impairment of the position and vibration senses is present. Electrophysiology studies and nerve conduction velocities confirm the involvement of the sensory nerves. The prognosis is usually poor with rare responses. It usually occurs in SCLC in association with anti-Hu antibodies.<sup>39</sup> Among lymphomas, HL is the frequent association.<sup>82-85</sup> Antibody tests are usually negative. Unlike dorsal column ganglionitis associated with SCLC, sensory-evoked potentials were not abolished in lymphoma-related neuronopathy. Nerve biopsy studies reveal axonal degeneration and perivascular inflammatory infiltrates.

*Pure autonomic neuronopathy.* In this exceptionally rare paraneoplastic disease of lymphomas, patients usually present with pandysautonomia (both sympathetic and parasympathetic dysfunction). Sympathetic system symptoms include anhidrosis, postural hypotension, and recurrent syncopes. Parasympathetic symptoms include sicca syndrome



(xerostomia and xerophthalmia), bowel and bladder hypomotility, lack of variation in the heart rate with respiration, erectile dysfunction, and impaired pupillary responses.<sup>87,88</sup> Antiganglionic acetylcholine receptor (AChR) antibodies are present in most, suggesting an autoimmune origin. Identification of these antibodies may help strengthen the diagnosis.

A thorough review of the PubMed literature revealed only three cases. Van Lieshout et al reported a rare and unusual presentation of cardiovascular autonomic neuropathy in a 22-year-old female student with early stage HL.<sup>89</sup> She had an intact parasympathetic heart rate control in combination with a postganglionic sympathetic lesion affecting the control of the vascular tree. Five months of polychemotherapy for HL resolved her autonomic symptoms except a dilated pupil and diminished right Achilles tendon reflex (constellation of these clinical findings are called Adie's syndrome). In another case report,<sup>90</sup> a limited form causing a tonic (adie) pupil has been reported in HL and Tr (DNER) antibodies. Hollenbeck et al<sup>88</sup> reported a case of an autoimmune autonomic ganglionopathy in a 65-year-old patient with prior history of small lymphocytic lymphoma (SLL). She became wheelchair bound due to severe postural hypotension unhelped by midodrine and fludrocortisone. Formal autonomic testing confirmed pandysautonomia. An autoantibody panel showed a high titer of nicotinic AChR antibody. A 4-week course of rituximab partially improved her symptoms, and the symptoms worsened after stopping it. Maintenance rituximab (every two months) followed by plasma exchange significantly decreased the nicotinic AChR antibody titers and consistent improvement in formal autonomic testing. She was able to walk independently after her treatment.

Another intriguing symptom identified in patients with HL is hypothermia. The cause for this is unknown. In a case report of hypothermia in a patient with transformed (from SLL) HL (Richter's transformation), combination chemotherapy was helpful in resolving the hypothermia. It was suggested to be a paraneoplastic syndrome by the authors.<sup>91</sup> They did not report any specific antibodies. In another review of 16 cases of hypothermia, most of them had an advanced stage of HL.

*Paraneoplastic myelopathy.* Paraneoplastic myelopathy is a rare disease. It presents with subacute myelitis and rapidly

ascending paralysis, frequently accompanied by a sensory level. CSF examination reveals pleocytosis and elevated protein. MRI shows a longitudinally extensive (greater than three vertebral segments) increased T2 signal abnormality with gadolinium-contrast enhancement. Usually, a definitive diagnosis can be made with certainty at autopsy. Leptomeningeal, epidural and, intramedullary metastases are the probable differential diagnoses. Lung and breast cancer are most commonly associated malignancies.<sup>81</sup> A review of the English literature by Ojeda et al revealed 22 cases of paraneoplastic necrotizing myelopathy.<sup>92</sup> Out of them, six were associated with lymphoma.<sup>92-95</sup> Serum or CSF may show onconeural antibodies such as CV2/CRMP5 and amphiphysin in solid tumors. However, lymphomas are usually seronegative. Specific therapy for paraneoplastic myelopathy is not known as it is a very rare disease. However, in one study, one-third of patients improved with immunosuppressive treatment Table 2.<sup>81</sup>

### Dermatologic Paraneoplastic Phenomena

**Paraneoplastic pemphigus vulgaris.** Paraneoplastic pemphigus vulgaris (PPV) is an autoimmune suprabasal epidermal blistering and painful disorder Table 3. PPV is almost exclusively caused by lymphoproliferative neoplasms.<sup>96</sup> NHL (39%), CLL (18%), and the Castleman's disease (18%) are the most common conditions associated with PPV.<sup>97</sup> Other less common associations include thymoma (6%), Waldenström's macroglobulinemia (WM) (1%), HL (<1%) and monoclonal gammopathy of uncertain origin (<1%). It is extremely resistant to therapy and portends a poor prognosis.

Both humoral- and cell-mediated immunity play a role in its pathogenesis. IgG antibodies to desmosomal and hemidesmosomal plakins and desmosomal desmogleins are thought to play a part in the pathogenesis. These interactions between the pathogenic antibodies and the epithelial cells lead to a loss of epithelial adhesion, leading to acantholysis. The production of these autoantibodies in lymphomas is not well understood.<sup>98</sup> Possible mechanisms include immune dysregulation caused by the lymphoma and the crossreactive antibodies (produced by the tumor cell antigens) to the epithelial antigens. The autoantibodies against envoplakin, periplakin along with anti-desmoglein 3, and the primary pathogenic antibody in

**Table 2.** Rare neurological paraneoplastic phenomena reported in the literature.

REFERENCE	PARANEOPLASTIC SYNDROME	NO.	ASSOCIATION	OTHER FEATURES
(48)	Brachial Plexopathy	1	HL	Treatment with corticosteroids helpful
(49)	Neoplastic Meningitis with eosinophilic Pleocytosis	1	HL	
(50)	Isolated Sympathetic Dysautonomia	1	HL	
(51, 52)	Acute Diffuse encephalitis	1	HL	
(53)	Ivory Vertebrae(Osteosclerotic localization)	1	HL	

**Abbreviation:** HL, Hodgkins Lymphoma.

**Table 3.** Rare dermatologic paraneoplastic phenomena reported in the literature.

REFERENCE	PN SYNDROME	NO.	ASSOCIATION	OTHER FEATURES
(1–3)	Hypertrophic Osteoarthropathy	1	Mediastinal HL in kids	
(4)	Psoriasiform Lesions	1	HL	
(5)	Necrobiotic xanthogranuloma		HL & CLL	
(6, 7)	Follicular Mucinosis	2	HL	Cutaneous lesions cleared partially with chemotherapy
(8)	Prurigo Nodularis	1	HL	Resolved with chemotherapy
(9–11)	Erythema Annulare Centrifugum	3	HL	Responded to vinblastine
(12)	Multiple Nevoid BCC Syndrome	1	HL	
(13)	Granulomatous Slack Skin	1	HL	
(14)	Bazex Syndrome	1	HL	
(15, 16)	Ichthyosiform Atrophy of the skin	2	HL	
(17)	Erythema Nodosum	1	HL	
(18)	Generalized Eczema	1	HL	
(19)	Alopecia Areata	1	HL	Young adult
(20)	Epithelioid Granulomas	55	HL	
(21)	Generalized Hyperhydrosis	1	HL	
(22)	Myorhythmia	1	HL	
(23)	PACGD	1	HL	
(4)	Psoriasiform Lesions	1	HL	
(6, 7)	Follicular Mucinosis	1	HL	Cutaneous lesions cleared with chemotherapy for HL
(5)	Necrobiotic xanthogranuloma Sn		HL & CLL	
(8)	Prurigo Nodularis	1	HL	Resolved with chemotherapy
(9–11)	Erythema Annulare Centrifugum	1	HL	Responded to vinblastine

**Abbreviations:** Bazex Syndrome, Acrokeratosis paraneoplastica with Ichthyosis; Myorhythmia:coarse alternating tremor; BCC, Basal Cell Carcinoma; PACGD, Progressive Atrophying Chronic Granulomatous Dermohypodermatitis; HL, Hodgkins Lymphoma; CLL, Chronic Lymphocytic Lymphoma.

Pemphigus vulgaris are the major pathogenic antibodies in PPV.<sup>99</sup> The role of cell-mediated immunity in the pathogenesis was<sup>100</sup> supported by its graft versus host disease (GVHD) type immune phenotype and its histological features such as interface dermatitis and keratinocyte dyskeratosis, which are characteristic of T-cell-mediated epithelial damage.

Two-thirds of the patients present with PPV before the diagnosis of their lymphoid malignancy.<sup>101</sup> The differential diagnoses usually include chemotherapy-induced mucositis, mucocutaneous drug reactions, erythema multiforme, cutaneous GVHD, and lichen planus.

#### Paraneoplastic autoimmune multiorgan syndrome.

Patients with this rare multisystem disorder present with severe blistering and painful erosions of the oral cavity and various other cutaneous findings ranging from classic Pemphigus vulgaris-like erosions to targeted lesions.<sup>102</sup> This disorder is clinically similar to erythema multiforme and papular lichenoid eruptions. It has a high rate of mortality due to its pulmonary involvement causing constrictive bronchiolitis obliterans.

The diagnosis of PPV and the paraneoplastic autoimmune multiorgan syndrome is suspected based on the clinical features of painful, progressive stomatitis and other characteristic

skin lesions. It is confirmed by its characteristic histopathological findings of acantholysis or lichenoid/interface dermatitis and demonstrating the presence of pathogenic antibodies in the presence of an underlying lymphoid neoplasm. Direct or indirect immunofluorescence microscopy and enzyme-linked immunosorbent assay can confirm the antibodies.

The treatment of PPV in lymphomas involves treating the underlying lymphoma and supportive therapy. Sometimes, resection of the underlying tumor such as thymoma or Castleman's disease leads to the remission of PPV.<sup>103,104</sup> However, this may take up to two years after resection. Treatment with high-dose steroids,<sup>105</sup> such as cyclophosphamide,<sup>106</sup> azathioprine,<sup>107</sup> mycophenolate mofetil,<sup>108</sup> and cyclosporine<sup>109</sup> are alternative treatment options. Other strategies include plasmapheresis,<sup>110</sup> alemtuzumab in CLL,<sup>111,112</sup> myeloablative doses of cyclophosphamide (200 mg/kg body weight daily for four days) without stem cell rescue in CLL,<sup>113</sup> and IVIG.<sup>114</sup> In one report, rituximab helped in achieving complete responses in 4 out of 13 patients.<sup>115</sup>

**Paraneoplastic ichthyosis.** Berrady et al published a case series of five patients with this disease jointly seen by a dermatologist and a hematologist.<sup>116</sup> Ichthyosis occurred two to



nine months after the initial symptoms of their hematological disorder. Two patients had NHL, one had HL, one had chronic myeloid leukemia, and one had an undifferentiated lymphoma. They reported that the ichthyosis progressed in step with the underlying blood disorder and regressed in three cases with the treatment of the underlying disease. The fact that the ichthyosis resolved with treatment of the underlying disease may well represent a paraneoplastic phenomenon.

**Paraneoplastic porphyria cutanea tarda.** HL is the most frequent association with paraneoplastic porphyria cutanea tarda (PCT). The PubMed literature showed, at least, five reported cases of PCT in patients with lymphoma.<sup>117–120</sup> One of them also had a syndrome of inappropriate diuretic hormone and peripheral neuropathy.<sup>119</sup> In a report from Mayo Clinic,<sup>117</sup> lymphoma and PCT occurred simultaneously in one patient and PCT happened three and one and half years before the diagnosis of lymphoma in two other patients. The PCT was not resolved by radiotherapy or chemotherapy of the lymphoma, although it was probably less symptomatic after the treatment.

### Hepatobiliary Paraneoplastic Phenomena

**Paraneoplastic hepatic sinusoidal ectasia and peliosis hepatis.** In the first published series of patients with paraneoplastic hepatic sinusoidal ectasia (HSE),<sup>121</sup> Six out of sixteen hepatic biopsies revealed sinusoidal dilatation and only one of these showed lymphomatous infiltration. In another report, it presented during a relapse of HL.<sup>122</sup> HSE may be the initial stage of peliosis hepatis (PH). PH is defined as blood-filled cystic cavities in the hepatic parenchyma. In seven patients with PH in HL, three of them were taking anabolic steroids<sup>123–125</sup> and others were not (Table 4).<sup>125–127</sup>

**Paraneoplastic intrahepatic cholestasis due to bile ductopenia (Vanishing bile duct syndrome or VBDS).** VBDS, characterized by intrahepatic cholestasis with a paucity of interlobular bile ducts, is a well-described paraneoplastic syndrome associated with HL. The cause is most likely immune-mediated given its association with drugs, GVHD, and autoimmune diseases apart from lymphomas. Biopsy reveals characteristic cholestasis due to the loss of bile ducts in the portal tracts without accompanying inflammation. Clinically,

it is characterized by hepatic failure.<sup>128</sup> Hepatic sinusoidal dilatation, a feature of VBDS, was shown to be present in HL patients presenting with systemic symptoms<sup>121</sup> without any direct involvement of liver by the lymphoma. There is evidence that the expression of intercellular adhesion molecules and the major histocompatibility complex antigens in response to the cytokines produced by the HL result in cytotoxicity to the biliary epithelium.<sup>129,130</sup>

It is important to rule out other causes of hepatic failure such as direct involvement of the liver by lymphoma, hemolysis, hepatotoxic viruses, drugs, and cholestatic jaundice due to obstructive lymphadenopathy. In a case series<sup>128</sup> of published VBDS in the literature, 18 of 39 patients achieved cure with the treatment of the underlying HL, which included steroids and combination chemotherapy. Although commonly associated with HL, it is also observed in T-cell-rich B-cell lymphoma<sup>131</sup> and peripheral T-cell lymphoma, not otherwise specified.<sup>132</sup>

### Renal Paraneoplastic Phenomena

Galloway introduced the term *paraneoplastic glomerulopathy* (PG) in the literature.<sup>133</sup> PG usually manifests as nephrotic syndrome due to minimal change nephropathy (MCN), membranous nephropathy, membranoproliferative glomerulonephritis (MPGN), focal segmental glomerulosclerosis, and amyloidosis. Other rarer causes include extracapillary glomerulonephritis (ECGN) and immunotactoid glomerulonephritis. They are common in HL and CLL and rare in NHL.

**HL and PG.** The incidence of nephrotic syndrome is low at 0.5%–1%<sup>134</sup> in HL. MCN (0.4%) and amyloidosis (0.1%) are common PGs as reported in a series of 1700 HL patients.

**Minimal change nephropathy.** The pathogenesis of MCN in HL is poorly understood. Studies support the hypothesis that an alteration of the malignant T-lymphocyte of HL, rather than the glomerular immune complexes, increases the permeability of the basement membrane.<sup>135</sup> It can appear before, during, or at relapse of the HL. Therefore, follow-up of HL should include evaluation for proteinuria.

In a retrospective study of 21 patients,<sup>134</sup> MCN was noted before the diagnosis of HL in 38%. In this subgroup, it was characterized by a steroid resistant nephrotic syndrome

**Table 4.** Rare Hepato-Biliary paraneoplastic phenomena reported in the literature.

REFERENCE	PARANEOPLASTIC SYNDROME	NO.	ASSOCIATION	OTHER FEATURES
(39, 40)	Secondary Sclerosing Cholangitis	1	HL	“Better prognosis than VBS”
(41, 42)	Fulminant non-alcoholic steatohepatitis	2	HL	Autopsy did not reveal any HL in the liver in both patients suggesting that it is a PN phenomenon. In one patient, it improved dramatically with HL treatment
(43–46)	Peliosis Hepatis	Multiple case reports	HL	Treatment for HL improved liver function tests in some reports
(47)	Hepatic Sinusoidal Ectasia	1	HL	

**Abbreviations:** VBS, Vanishing Bile duct Syndrome; HL, Hodgkins Lymphoma.





(50%). It appeared after the diagnosis of HL in 42% and appeared at the time of relapse in 55% of the cases. In 19%, the two diseases were diagnosed simultaneously. It is of interest to note that the effective treatment of HL with polychemo-therapy resulted in the disappearance of the MCN. The predominant morphological subtype of HL associated with this disorder was nodular sclerosis (71% of patients) in one case series<sup>134</sup> and mixed cellularity in another.<sup>135</sup>

**Amyloidosis in HL.** Effective therapies for HL may be the reason for the decreased incidence of amyloidosis in the recent years as most of the published cases were in the 1970s.<sup>136</sup> The associated amyloid protein was assumed to be AA (amyloid A) as amyloidosis occurs in the late, inflammatory stages of HL in the absence of a monoclonal component. Franklin et al separated the protein subunits in the amyloid fibrils of patients and identified AA as the amyloid protein associated with two patients with HL.<sup>137</sup>

**Other PGs in HL.** Apart from the frequent MCN and amyloidosis, other less common PGs related to HL include focal segmental glomerulosclerosis (four patients), MPGN (two patients), membranous nephropathy (five patients), and ECGN (six patients).<sup>136,138–142</sup>

**CLL and the related B-cell lymphoproliferative disorders and PG.** Paraneoplastic glomerulopathies in CLL and the related B-cell lymphoproliferative disorders are rare. In the first retrospective case series of 13 patients published in 1992,<sup>143</sup> a clear-cut relationship between the PG and the B-cell lymphoproliferative disorder was established in nine cases. Out of them, five patients had cryoglobulin-induced MPGN. Two had MPGN or mesangial hypertrophy with circulating and deposited noncryoprecipitating monoclonal IgG-kappa and IgM-kappa, respectively. In the remaining two patients, monotypic IgG-kappa glomerular deposits exhibiting fibrillary organization was observed in association with MPGN despite an absence of circulating M-component. Chlorambucil alone induced complete remission of nephrotic syndrome in five patients. This data proved that the PG associated with

CLL and the related B-cell lymphoproliferative disorders was not serendipitous and also provided insight about the pathophysiology.

In a recent 2015 retrospective analysis,<sup>144</sup> out of 15 patients with CLL/SLL, kidney biopsies showed CLL/SLL-specific monoclonal infiltrate in 10 biopsies and glomerulopathy in 9 biopsies. After treatment of the underlying CLL, improvement of the renal function was observed in 7 of 11 and remission of nephrotic syndrome in 5 of 7 patients.

The CLL associated PG is characterized by the following features.<sup>1</sup> In 50%, a diagnosis of both CLL and the PG occur simultaneously. Nephrotic syndrome is present in 85%, and one-third of them develop renal failure. Dysproteinemia is present in 50% of patients in the CLL, and this is in contrast to the 5%–10% in CLL without renal involvement. Chemotherapy directed at CLL (Chlorambucil) can cause complete remission of the PG and improvement of renal function.<sup>143</sup>

Other rare PGs associated with CLL include immunotactoid glomerulopathy and glomerulonephritis with organized microtubular monoclonal immunoglobulin deposition (GOMMID).<sup>146–148</sup> In GOMMID, the cytoplasm of circulating lymphocytes contains organized microtubular structures.

**NHLs and PG.** In a total of 47 patients with NHL and PG reported in the literature,<sup>136,138,139,142</sup> 12 cases were due to MPGN and 12 due to ECGN. MCN is rare in NHL unlike in HL. A clear-cut association between NHL and the glomerulopathy can be established only in patients with cryoglobulinemic MPGN and in those with immunotactoid glomerulonephritis with monotypic Ig deposits Table 5.<sup>1</sup>

## Conclusion

Paraneoplastic disorders in lymphomas are very rare. HL is the most commonly associated lymphoproliferative disease. They can present before, at the time of diagnosis, during remission, or at relapse of the lymphoma. So, a high index of suspicion is required as some of these syndromes are reversible with effective

**Table 5.** Rare metabolic paraneoplastic phenomena reported in the literature.

REFERENCE	PARANEOPLASTIC SYNDROME	NO.	ASSOCIATION	OTHER FEATURES
(24)	Hypoglycemia	1	HL	Due to insulin receptor antibody
(25)	Lactic acidosis	1	HL	Responded to chemotherapy
(26–28)	Hypouricemia	1	HL	
(29)	Hypertension	1	HL	Childhood HL
(30, 31)	SIADH	1	HL	
(32)	Neoplastic fever	21	HL	20 responded to naproxen within 12 hrs
(33)	Night sweats	9/34	HL	9 of 34 has recurrent symptoms as the only symptom
(34–37)	Hypercalcemia		HL, CLL	Calcitriol is proven as the cause
(38)	Hyper Aldosteronism	1	NHL	

**Abbreviations:** No, Number of patients; HL, Hodgkin Lymphoma; NHL, Non Hodgkins Lymphoma; CLL, Chronic Lymphocytic Leukemia.



chemotherapy for the underlying lymphoma. Others need specific therapy such as steroids and immunosuppressive therapy. The rare nature of these diseases makes it difficult to identify new syndromes as most of the literature is based on case reports and small case series. However, significant progress has been achieved in the last 10 years due to defined clinical criteria, identification of the pathogenic culprit antibodies, early detection of the lymphomas, and efficient therapies for the lymphoma.

### Author Contributions

Wrote the final manuscript: PT, AK, and JK. Collection and organization of the data, the creation of tables, and wrote the initial article: VSB and MG. Senior author, who revised and approved the final article: PB. All authors reviewed and approved of the final manuscript.

### REFERENCES

- Ronco PM. Paraneoplastic glomerulopathies: new insights into an old entity. *Kidney Int.* 1999;56(1):355–377.
- Tandra P, Krishnamurthy J, Bhatt VR, Newman K, Armitage JO, Akhtari M. Autoimmune cytopenias in chronic lymphocytic leukemia, facts and myths. *Mediterr J Hematol Infect Dis.* 2013;5(1):e2013068.
- Diehl LF, Ketchum LH. Autoimmune disease and chronic lymphocytic leukemia: autoimmune hemolytic anemia, pure red cell aplasia, and autoimmune thrombocytopenia. *Semin Oncol.* 1998;25(1):80–97.
- Barker RN, Hall AM, Standen GR, Jones J, Elson CJ. Identification of T-cell epitopes on the Rhesus polypeptides in autoimmune hemolytic anemia. *Blood.* 1997;90(7):2701–2715.
- Hall AM, Vickers MA, McLeod E, Barker RN. Rh autoantigen presentation to helper T cells in chronic lymphocytic leukemia by malignant B cells. *Blood.* 2005;105(5):2007–2015.
- Kipps TJ, Carson DA. Autoantibodies in chronic lymphocytic leukemia and related systemic autoimmune diseases. *Blood.* 1993;81(10):2475–2487.
- Semple JW, Provan D, Garvey MB, Freedman J. Recent progress in understanding the pathogenesis of immune thrombocytopenia. *Curr Opin Hematol.* 2010;17(6):590–595.
- Johnsen J. Pathogenesis in immune thrombocytopenia: new insights. *Hematology Am Soc Hematol Educ Program.* 2012;2012:306–312.
- Cartron J, Fior R, Boue F, Tertian G, Gane P, Cartron JP. Non Hodgkin's lymphoma presenting as neutropenia related to an IgM monoclonal anti-i antibody. *Hematol Cell Ther.* 1996;38(2):225–230.
- Bluestone JA, Tang Q. How do CD4+CD25+ regulatory T cells control autoimmunity? *Curr Opin Immunol.* 2005;17(6):638–642.
- Beyer M, Kochanek M, Darabi K, et al. Reduced frequencies and suppressive function of CD4+CD25hi regulatory T cells in patients with chronic lymphocytic leukemia after therapy with fludarabine. *Blood.* 2005;106(6):2018–2025.
- Akhtari M, Curtis B, Waller EK. Autoimmune neutropenia in adults. *Autoimmun Rev.* 2009;9(1):62–66.
- Aryal MR, Bhatt VR, Tandra P, et al. Autoimmune neutropenia in multiple myeloma and the role of clonal T-cell expansion: evidence of cross-talk between B-cell and T-cell lineages? *Clin Lymphoma Myeloma Leuk.* 2014;14(1):e19–e23.
- Voog E, Morschhauser F, Solal-Celigny P. Neutropenia in patients treated with rituximab. *N Engl J Med.* 2003;348(26):2691–2694. [discussion 2691–4].
- Roberts L, Lucas G, Green L, et al. Autoimmune neutropenia following therapy for chronic lymphocytic leukaemia: a report of three cases. *Br J Haematol.* 2007;136(2):348–349.
- Sallah S, Sigounas G, Vos P, Wan JY, Nguyen NP. Autoimmune hemolytic anemia in patients with non-Hodgkin's lymphoma: characteristics and significance. *Ann Oncol.* 2000;11(12):1571–1577.
- Xiros N, Binder T, Anger B, Bohlke J, Heimpel H. Idiopathic thrombocytopenic purpura and autoimmune hemolytic anemia in Hodgkin's disease. *Eur J Haematol.* 1988;40(5):437–441.
- Hagler KT, Zori RT, Yuan CM, Gray BA, Moreb JS. Diagnosis of an early precursor-B-ALL presenting with hyper eosinophilia using FISH on immunomagnetically selected CD19+ cells. *Clin Adv Hematol Oncol.* 2005;3(1):62–64.
- Rai KR, Sawitsky A, Cronkite EP, Chanana AD, Levy RN, Pasternack BS. Clinical staging of chronic lymphocytic leukemia. *Blood.* 1975;46(2):219–234.
- Binet JL, Auquier A, Dighiero G, et al. A new prognostic classification of chronic lymphocytic leukemia derived from a multivariate survival analysis. *Cancer.* 1981;48(1):198–206.
- Guenther FW, Bube FW. On the diagnosis and therapy of peracute hemolytic anemia associated with thrombocytopenia caused by autoimmune bodies (Evans-syndrome). *Arch Kinderheilkd.* 1962;167:155–159.
- Silverstein MN, Heck FJ. Acquired hemolytic anemia and associated thrombocytopenic purpura: with special reference to Evans' syndrome. *Proc Staff Meet Mayo Clin.* 1962;37:122–128.
- Hamblin TJ. Autoimmune complications of chronic lymphocytic leukemia. *Semin Oncol.* 2006;33(2):230–239.
- Di Biagio E, Sanchez-Borges M, Desenne JJ, Suarez-Chacon R, Somoza R, Acquatella G. Eosinophilia in Hodgkin's disease: a role for interleukin 5. *Int Arch Allergy Immunol.* 1996;110(3):244–251.
- Trojan A, Meier R, Licht A, Taverna C. Eosinophilic pneumonia after administration of fludarabine for the treatment of non-Hodgkin's lymphoma. *Ann Hematol.* 2002;81(9):535–537.
- Voutsadakis IA. Fludarabine-induced eosinophilia: case report. *Ann Hematol.* 2002;81(5):292–293.
- Robak T, Sysa-Jedrzejowska A, Robak E, Dabkowski J, Blasinska-Morawiec M. 2-chlorodeoxyadenosine (cladribine) induced allergic cutaneous reactions with eosinophilia in a patient with B-cell chronic lymphocytic leukemia. *J Med.* 1997;28(3–4):199–209.
- Randi ML, Rossi C, Barbone E, Pietrogrande F, Girolami A. Incidence of thrombocytosis in lymphomas. *Leuk Lymphoma.* 1992;7(1–2):139–141.
- Gesierich W, Munker R, Geiersberger U, Pohlmann H, Brack N, Hartenstein R. Spontaneous bleeding in a patient with malignant lymphoma: a case of acquired hemophilia. *Onkologie.* 2000;23(6):584–588.
- Rao KP, Kizer J, Jones TJ, Anunciado A, Pepkowitz SH, Lazarchick J. Acquired von Willebrand's syndrome associated with an extranodal pulmonary lymphoma. *Arch Pathol Lab Med.* 1988;112(1):47–50.
- Hunault-Berger M, Rachieru P, Ternisien C, et al. Acquired von Willebrand disease and lymphoproliferative syndromes. *Presse Med.* 2001;30(5):209–212.
- Genvesse I, Buttgerit F, Spath-Schwalbe E, Ziemer S, Eucker J, Possinger K. Arterial thrombosis associated with anticardiolipin and anti-beta-2-glycoprotein-I antibodies in patients with non-Hodgkin's lymphoma: a report of two cases. *Eur J Haematol.* 2000;65(5):344–347.
- Gultekin SH, Rosenfeld MR, Voltz R, Eichen J, Posner JB, Dalmau J. Paraneoplastic limbic encephalitis: neurological symptoms, immunological findings and tumour association in 50 patients. *Brain.* 2000;123(pt 7):1481–1494.
- Gultekin S, Humayun, et al. Paraneoplastic limbic encephalitis: neurological symptoms, immunological findings and tumour association in 50 patients. 2000:1481–1494.
- Lancaster E, Martinez-Hernandez E, Titulaer MJ, et al. Antibodies to metabotropic glutamate receptor 5 in the Ophelia syndrome. *Neurology.* 2011;77(18):1698–1701.
- Mat A, Adler H, Merwick A, et al. Ophelia syndrome with metabotropic glutamate receptor 5 antibodies in CSF. *Neurology.* 2013;80(14):1349–1350.
- Epaulard O, Courby S, Pavese P, et al. Paraneoplastic acute diffuse encephalitis revealing Hodgkin's disease. *Leuk Lymphoma.* 2004;45(12):2509–2512.
- Graus F, Keime-Guibert F, Rene R, et al. Anti-Hu-associated paraneoplastic encephalomyelitis: analysis of 200 patients. *Brain.* 2001;124(pt 6):1138–1148.
- Dogel D, Beuing O, Koenigsmann M, Dietsch S. Paraneoplastic limbic encephalitis resulting from non-Hodgkin-lymphoma: two case reports. *Fortschr Neurol Psychiatr.* 2008;76(1):41–46.
- Rajappa S, Digumarti R, Immaneni SR, Parage M. Primary renal lymphoma presenting with paraneoplastic limbic encephalitis. *J Clin Oncol.* 2007;25(24):3783–3785.
- Markert A, May A, Weber J, Rottenburger C, Rauer S, Veelken H. Bilateral renal lymphoma after paraneoplastic limbic encephalitis. *J Clin Oncol.* 2009;27(7):1142–1144.
- Semnic M, Jovanovic D, Petrovic D, Nad I, Semnic R. Paraneoplastic limbic encephalitis in a patient with non-Hodgkin's lymphoma. *Arch Oncol.* 2004;12:71–73.
- Dalmau J, Rosenfeld MR. Paraneoplastic syndromes of the CNS. *Lancet Neurol.* 2008;7(4):327–340.
- Hammack J, Kotanides H, Rosenblum MK, Posner JB. Paraneoplastic cerebellar degeneration. II. Clinical and immunologic findings in 21 patients with Hodgkin's disease. *Neurology.* 1992;42(10):1938–1943.
- Bernal F, Shams'ili S, Rojas I, et al. Anti-Tr antibodies as markers of paraneoplastic cerebellar degeneration and Hodgkin's disease. *Neurology.* 2003;60(2):230–234.
- Trotter JL, Hendin BA, Osterland CK. Cerebellar degeneration with Hodgkin disease. An immunological study. *Arch Neurol.* 1976;33(9):660–661.
- Greene M, Lai Y, Baella N, Dalmau J, Lancaster E. Antibodies to Delta/notch-like epidermal growth factor-related receptor in patients with anti-Tr, paraneoplastic cerebellar degeneration, and Hodgkin lymphoma. *JAMA Neurol.* 2014;71(8):1003–1008.



48. de Graaff E, Maat P, Hulsenboom E, et al. Identification of delta/notch-like epidermal growth factor-related receptor as the Tr antigen in paraneoplastic cerebellar degeneration. *Ann Neurol*. 2012;71(6):815–824.
49. Silveis Smitt P, Kinoshita A, De Leeuw B, et al. Paraneoplastic cerebellar ataxia due to autoantibodies against a glutamate receptor. *N Engl J Med*. 2000; 342(1):21–27.
50. Marignier R, Chenevier F, Rogemond V, et al. Metabotropic glutamate receptor type 1 autoantibody-associated cerebellitis: a primary autoimmune disease? *Arch Neurol*. 2010;67(5):627–630.
51. Shams'ili S, Grefkens J, de Leeuw B, et al. Paraneoplastic cerebellar degeneration associated with antineuronal antibodies: analysis of 50 patients. *Brain*. 2003; 126(pt 6):1409–1418.
52. Shu-Leong H. Available at: <http://www.movementdisorders.org/MDS/About/Movement-Disorder-Overviews/Chorea--Huntingtons-Disease.htm>
53. Vigliani MC, Honnorat J, Antoine JC, et al. Chorea and related movement disorders of paraneoplastic origin: the PNS EuroNetwork experience. *J Neurol*. 2011;258(11):2058–2068.
54. Vernino S, Tuite P, Adler CH, et al. Paraneoplastic chorea associated with CRMP-5 neuronal antibody and lung carcinoma. *Ann Neurol*. 2002;51(5): 625–630.
55. Helfgott SM. Stiff-man syndrome: from the bedside to the bench. *Arthritis Rheum*. 1999;42(7):1312–1320.
56. Solimena M, Folli F, Aparisi R, Pozza G, De Camilli P. Autoantibodies to GABA-ergic neurons and pancreatic beta cells in stiff-man syndrome. *N Engl J Med*. 1990;322(22):1555–1560.
57. Whiteley AM, Swash M, Urlich H. Progressive encephalomyelitis with rigidity its relation to 'subacute myoclonic spinal neuronitis' and to the 'stiff man syndrome'. *Brain*. 1976;99(1):27–42.
58. Ferrari P, Federico M, Grimaldi LM, Silingardi V. Stiff-man syndrome in a patient with Hodgkin's disease. An unusual paraneoplastic syndrome. *Haematologica*. 1990;75(6):570–572.
59. Schmidt C, Freilinger T, Lieb M, et al. Progressive encephalomyelitis with rigidity and myoclonus preceding otherwise asymptomatic Hodgkin's lymphoma. *J Neurol Sci*. 2010;291(1–2):118–120.
60. McKeon A, Martinez-Hernandez E, Lancaster E, et al. Glycine receptor autoimmune spectrum with stiff-man syndrome phenotype. *JAMA Neurol*. 2013; 70(1):44–50.
61. Gutmann B, Crivellaro C, Mitterer M, et al. Paraneoplastic stiff-person syndrome, heterotopic soft tissue ossification and gonarthrosis in a HLA B27-positive woman preceding the diagnosis of Hodgkin's lymphoma. *Haematologica*. 2006; 91:ECR59.
62. Hajj-Ali RA, Singhal AB, Benseler S, Molloy E, Calabrese LH. Primary angitis of the CNS. *Lancet Neurol*. 2011;10(6):561–572.
63. Delobel P, Brassat D, Danjoux M, et al. Granulomatous angitis of the central nervous system revealing Hodgkin's disease. *J Neurol*. 2004;251(5):611–612.
64. Fuehrer NE, Hammack JE, Morris JM, Kaufmann TJ, Giannini C. Teaching NeuroImages: granulomatous angitis of the CNS associated with Hodgkin lymphoma. *Neurology*. 2011;77(19):e110–e111.
65. Rosen CL, DePalma L, Morita A. Primary angitis of the central nervous system as a first presentation in Hodgkin's disease: a case report and review of the literature. *Neurosurgery*. 2000;46(6):1504–1508. [discussion 1508–10].
66. Wong A. An update on opsoclonus. *Curr Opin Neurol*. 2007;20(1):25–31.
67. Briongos-Figuero LS, Gomez-Traveso T, Perez-Castrillon JL. T-cell primary leptomeningeal lymphoma in cerebellopontine angle. *BMJ Case Rep*. 2015;2015: doi:10.1136/bcr-2014-208602.
68. Tsuzaka K, Aimoto Y, Minami N, Moriwaka F, Tashiro K. A case of primary intracranial malignant lymphoma presenting opsoclonus-polymyoclonia syndrome. *Rinsbo Shinkeigaku*. 1993;33(2):194–198.
69. Kay CL, Davies-Jones GA, Singal R, Winfield DA. Paraneoplastic opsoclonus-myoclonus in Hodgkin's disease. *J Neurol Neurosurg Psychiatry*. 1993;56(7): 831–832.
70. Hughes RA, Britton T, Richards M. Effects of lymphoma on the peripheral nervous system. *JR Soc Med*. 1994;87(9):526–530.
71. Vallat JM, Vital C, LeBoutet MJ, Loubet A, Brechenmacher C. Abnormal proliferation of intraergastoplasmic microfilaments in myelinated schwann cells: ultrastructural study of two cases. *J Neuropathol Exp Neurol*. 1982;41(4): 460–465.
72. Tomita M, Koike H, Kawagashira Y, et al. Clinicopathological features of neuropathy associated with lymphoma. *Brain*. 2013;136(pt 8):2563–2578.
73. Amundson DE, Goodman JC. Hodgkin's disease in association with Guillain-Barre-Strohl syndrome: case report. *Mil Med*. 1983;148(6):512–513.
74. Cuttner J, Meyer R. Guillain-Barre syndrome in a patient with Hodgkin's disease. *Mt Sinai J Med*. 1978;45(3):415–417.
75. Julien J, Vital C, Aupy G, Laguery A, Darriet D, Brechenmacher C. Guillain-Barre syndrome and Hodgkin's disease—ultrastructural study of a peripheral nerve. *J Neurol Sci*. 1980;45(1):23–27.
76. Bishay RH, Paton J, Abraham V. Variant Guillain-Barre syndrome in a patient with non-Hodgkin's lymphoma. *Case Rep Hematol*. 2015;2015:979237.
77. Wei D, Ma XL, Zhang SQ, Bi XY. Atypical Guillain-Barre syndrome caused by primary diffuse large B-cell lymphoma originating from dorsal root ganglion. *CNS Neurosci Ther*. 2015;21(8):674–676.
78. Machida H, Shinohara T, Hatakeyama N, et al. CD5-positive diffuse large B cell lymphoma infiltrating the central nervous system presenting Guillain-Barre-like syndrome after chemotherapy. *J Clin Exp Hematop*. 2012;52(3):199–204.
79. Polo-Romero FJ, Sanchez-Beteta P, Perona-Buendia P, Perez-Garcia AM. Guillain-Barre syndrome as first presentation of non-Hodgkin lymphoma. *Neurologia*. 2012;27(8):511–513.
80. Schold SC, Cho ES, Somasundaram M, Posner JB. Subacute motor neuropathy: a remote effect of lymphoma. *Ann Neurol*. 1979;5(3):271–287.
81. Flanagan EP, McKeon A, Lennon VA, et al. Paraneoplastic isolated myelopathy: clinical course and neuroimaging clues. *Neurology*. 2011;76(24):2089–2095.
82. Horwich MS, Cho L, Porro RS, Posner JB. Subacute sensory neuropathy: a remote effect of carcinoma. *Ann Neurol*. 1977;2(1):7–19.
83. Case records of the Massachusetts General Hospital. Weekly clinicopathological exercises. Case 8–1990. A 45-year-old woman with Hodgkin's disease and a neurologic disorder. *N Engl J Med*. 1990;322(8):531–543.
84. Oh BC, Lim YM, Kwon YM, Khang SK, Kim KK. A case of Hodgkin's lymphoma associated with sensory neuropathy. *J Korean Med Sci*. 2004;19(1): 130–133.
85. Plante-Bordeneuve V, Baudrimont M, Gorin NC, Gherardi RK. Subacute sensory neuropathy associated with Hodgkin's disease. *J Neurol Sci*. 1994;121(2): 155–158.
86. Sagar HJ, Read DJ. Subacute sensory neuropathy with remission: an association with lymphoma. *J Neurol Neurosurg Psychiatry*. 1982;45(1):83–85.
87. Koike H, Watanabe H, Sobue G. The spectrum of immune-mediated autonomic neuropathies: insights from the clinicopathological features. *J Neurol Neurosurg Psychiatry*. 2013;84(1):98–106.
88. Hollenbeck R, Black BK, Peltier AC, et al. Long-term treatment with rituximab of autoimmune autonomic ganglionopathy in a patient with lymphoma. *Arch Neurol*. 2011;68(3):372–375.
89. van Lieshout JJ, Wieling W, van Montfrans GA, et al. Acute dysautonomia associated with Hodgkin's disease. *J Neurol Neurosurg Psychiatry*. 1986;49(7): 830–832.
90. Horta E, McKeon A, Lennon VA, Benarroch EE. Reversible paraneoplastic tonic pupil with PCA-Tr IgG and Hodgkin lymphoma. *Neurology*. 2012;78(20): 1620–1622.
91. Shepshelovich D, Shpilberg O, Lahav N, et al. Hodgkin lymphoma and hypothermia: case report and review of the literature. *Acta Haematol*. 2014;131(4): 227–230.
92. Ojeda VJ. Necrotizing myelopathy associated with malignancy. A clinicopathological study of two cases and literature review. *Cancer*. 1984;53(5):1115–1123.
93. Williams RA, Billings JJ, De Gruchy GC. Acute myelitis complicating lymphosarcoma. *Med J Aust*. 1962;49(1):128–133.
94. Richter RB, Moore RY. Non-invasive central nervous system disease associated with lymphoid tumors. *Johns Hopkins Med J*. 1968;122(5):271–283.
95. Whiteley AM, Hauw JJ, Escourolle R. A pathological survey of 41 cases of acute intrinsic spinal cord disease. *J Neurol Sci*. 1979;42(2):229–242.
96. Zhu X, Zhang B. Paraneoplastic pemphigus. *J Dermatol*. 2007;34(8):503–511.
97. Kaplan I, Hodak E, Ackerman L, Mimouni D, Anhalt GJ, Calderon S. Neoplasms associated with paraneoplastic pemphigus: a review with emphasis on non-hematologic malignancy and oral mucosal manifestations. *Oral Oncol*. 2004; 40(6):553–562.
98. Billet SE, Grando SA, Pittelkow MR. Paraneoplastic autoimmune multiorgan syndrome: review of the literature and support for a cytotoxic role in pathogenesis. *Autoimmunity*. 2006;39(7):617–630.
99. Li J, Bu DF, Huang YC, Zhu XJ. Role of autoantibodies against the linker subdomains of envoplakin and periplakin in the pathogenesis of paraneoplastic pemphigus. *Chin Med J (Engl)*. 2009;122(5):486–495.
100. Reich K, Brinck U, Letschert M, et al. Graft-versus-host disease-like immunophenotype and apoptotic keratinocyte death in paraneoplastic pemphigus. *Br J Dermatol*. 1999;141(4):739–746.
101. Sehgal VN, Srivastava G. Paraneoplastic pemphigus/paraneoplastic autoimmune multiorgan syndrome. *Int J Dermatol*. 2009;48(2):162–169.
102. Villette B, Tulliez M. Erythema annulare centrifugum and Hodgkin's disease. *Ann Dermatol Venerol*. 1990;117(11):889–890.
103. Fang Y, Zhao L, Yan F, Cui X, Xia Y, Duren A. A critical role of surgery in the treatment for paraneoplastic pemphigus caused by localized Castleman's disease. *Med Oncol*. 2010;27(3):907–911.
104. Nikolskaia OV, Nousari CH, Anhalt GJ. Paraneoplastic pemphigus in association with Castleman's disease. *Br J Dermatol*. 2003;149(6):1143–1151.
105. Frew JW, Murrell DF. Current management strategies in paraneoplastic pemphigus (paraneoplastic autoimmune multiorgan syndrome). *Dermatol Clin*. 2011; 29(4):607–612.
106. Hertzberg MS, Schifter M, Sullivan J, Stapleton K. Paraneoplastic pemphigus in two patients with B-cell non-Hodgkin's lymphoma: significant responses to cyclophosphamide and prednisolone. *Am J Hematol*. 2000;63(2):105–106.





107. Camisa C, Helm TN, Liu YC, et al. Paraneoplastic pemphigus: a report of three cases including one long-term survivor. *J Am Acad Dermatol.* 1992;27(4):547–553.
108. Williams JV, Marks JG Jr, Billingsley EM. Use of mycophenolate mofetil in the treatment of paraneoplastic pemphigus. *Br J Dermatol.* 2000;142(3):506–508.
109. Gergely L, Varoczy L, Vadasz G, Remenyik E, Illes A. Successful treatment of B cell chronic lymphocytic leukemia-associated severe paraneoplastic pemphigus with cyclosporin A. *Acta Haematol.* 2003;109(4):202–205.
110. Izaki S, Yoshizawa Y, Kitamura K, et al. Paraneoplastic pemphigus: potential therapeutic effect of plasmapheresis. *Br J Dermatol.* 1996;134(5):987–989.
111. Hohwy T, Bang K, Steiniche T, Peterslund NA, d'Amore F. Alemtuzumab-induced remission of both severe paraneoplastic pemphigus and leukaemic bone marrow infiltration in a case of treatment-resistant B-cell chronic lymphocytic leukaemia. *Eur J Haematol.* 2004;73(3):206–209.
112. Bech R, Baumgartner-Nielsen J, Peterslund NA, Steiniche T, Deleuran M, d'Amore F. Alemtuzumab is effective against severe chronic lymphocytic leukaemia-associated paraneoplastic pemphigus. *Br J Dermatol.* 2013;169(2):469–472.
113. Nousari HC, Brodsky RA, Jones RJ, Grever MR, Anhalt GJ. Immunoablative high-dose cyclophosphamide without stem cell rescue in paraneoplastic pemphigus: report of a case and review of this new therapy for severe autoimmune disease. *J Am Acad Dermatol.* 1999;40(5 pt 1):750–754.
114. Nanda M, Nanda A, Al-Sabah H, Dvorak R, Alsaleh QA. Paraneoplastic pemphigus in association with B-cell lymphocytic leukemia and hepatitis C: favorable response to intravenous immunoglobulins and prednisolone. *Int J Dermatol.* 2007;46(7):767–769.
115. Anan T, Shimizu F, Hatano Y, Okamoto O, Katagiri K, Fujiwara S. Paraneoplastic pemphigus associated with corneal perforation and cutaneous alternariosis: a case report and review of cases treated with rituximab. *J Dermatol.* 2011;38(11):1084–1089.
116. Berrady R, Baybay H, Khammar Z, et al. Acquired ichthyosis and haematological malignancies: five cases. *Ann Dermatol Venereol.* 2012;139(1):9–14.
117. Maughan WZ, Muller SA, Perry HO. Porphyria cutanea tarda associated with lymphoma. *Acta Derm Venereol.* 1979;59:55–58.
118. Rayhanzadeh S, Shoss RG, Noyes J. Letter: Porphyria cutanea tarda associated with lymphosarcoma. *Arch Dermatol.* 1975;111(1):129.
119. Lai CL, Wu PC, Lin HJ, Wong KL. Case report of symptomatic porphyria cutanea tarda associated with histiocytic lymphoma. *Cancer.* 1984;53(3):573–576.
120. Haber L. Porphyria cutanea tarda. *Clinical Dermatology.* Vol 6. 1977:6.
121. Bruguera M, Caballero T, Carreras E, Aymerich M, Rodes J, Rozman C. Hepatic sinusoidal dilatation in Hodgkin's disease. *Liver.* 1987;7(2):76–80.
122. Bain BJ, Chong KC, Coghlan SJ, Roberts SJ. Hepatic sinusoidal ectasia in association with Hodgkin's disease. *Postgrad Med J.* 1982;58(677):182–184.
123. Bagheri SA, Boyer JL. Peliosis hepatitis associated with androgenic-anabolic steroid therapy. A severe form of hepatic injury. *Ann Intern Med.* 1974;81(5):610–618.
124. McDonald EC, Speicher CE. Peliosis hepatitis associated with administration of oxymetholone. *JAMA.* 1978;240(3):243–244.
125. Taxy JB. Peliosis: a morphologic curiosity becomes an iatrogenic problem. *Hum Pathol.* 1978;9(3):331–340.
126. Weickel A. Peliosis of the inner organs. *Zentralbl Allg Pathol.* 1957;96(3–4):113–118.
127. Duffaud-Thierman D, Hecht Y, Callard P, de St Maur P, Levy VG, Smadja M. Hepatic peliosis. Clinical and paraclinical aspects apropos of 6 cases of unusual etiology. *Med Chir Dig.* 1977;6(8):519–532.
128. Rota Scalabrini D, Caravelli D, Carnevale Schianca F, et al. Complete remission of paraneoplastic vanishing bile duct syndrome after the successful treatment of Hodgkin's lymphoma: a case report and review of the literature. *BMC Res Notes.* 2014;7:529.
129. Adams DH, Hubscher SG, Shaw J, Rothlein R, Neuberger JM. Intercellular adhesion molecule 1 on liver allografts during rejection. *Lancet.* 1989;2(8672):1122–1125.
130. Reynoso-Paz S, Coppel RL, Ansari AA, Gershwin ME. Vanishing bile duct syndromes: considerations of the immunobiology of autoimmune biliary diseases. *Isr Med Assoc J.* 1999;1(1):37–44.
131. Gagnon MF, Nguyen BN, Olney HJ, Lemieux B. Vanishing bile duct syndrome arising in a patient with T-cell-rich large B-cell lymphoma. *J Clin Oncol.* 2013;31(20):e357–e359.
132. Gill RM, Ferrell LD. Vanishing bile duct syndrome associated with peripheral T cell lymphoma, not otherwise specified, arising in a posttransplant setting. *Hepatology.* 2010;51(5):1856–1857.
133. Galloway J. Remarks on Hodgkin's disease. *BMJ.* 1922;2:1201.
134. Audard V, Larousserie F, Grimbert P, et al. Minimal change nephrotic syndrome and classical Hodgkin's lymphoma: report of 21 cases and review of the literature. *Kidney Int.* 2006;69(12):2251–2260.
135. Moorthy AV, Zimmerman SW, Burkholder PM. Nephrotic syndrome in Hodgkin's disease. Evidence for pathogenesis alternative to immune complex deposition. *Am J Med.* 1976;61(4):471–477.
136. Moulin B, Chantrel F, Petitjean P, Ronco PM. Chronic lymphoproliferative disorders and glomerular diseases: review of the literature and pathophysiological considerations. *J Nephrol.* 1995;8:20–26.
137. Franklin EC, Pras M, Levin M, Frangione B. The partial amino acid sequence of the major low molecular weight component of two human amyloid fibrils. *FEBS Lett.* 1972;22(1):121–123.
138. Eagen JW. Glomerulopathies of neoplasia. *Kidney Int.* 1977;11(5):297–303.
139. Alpers CE, Cotran RS. Neoplasia and glomerular injury. *Kidney Int.* 1986;30(4):465–473.
140. Plager J, Stutzman L. Acute nephrotic syndrome as a manifestation of active Hodgkin's Disease. Report of four cases and review of the literature. *Am J Med.* 1971;50(1):56–66.
141. Kramer P, Sizoo W, Twiss EE. Nephrotic syndrome in Hodgkin's disease. Report of five cases and review of the literature. *Nett J Med.* 1981;24(3):114–119.
142. Dabbs DJ, Striker LM, Mignon F, Striker G. Glomerular lesions in lymphomas and leukemias. *Am J Med.* 1986;80(1):63–70.
143. Moulin B, Ronco PM, Mougnot B, Francois A, Fillastre JP, Mignon F. Glomerulonephritis in chronic lymphocytic leukemia and related B-cell lymphomas. *Kidney Int.* 1992;42(1):127–135.
144. Poitou-Verkinder AL, Francois A, Drieux F, et al. The spectrum of kidney pathology in B-cell chronic lymphocytic leukemia/small lymphocytic lymphoma: a 25-year multicenter experience. *PLoS One.* 2015;10(3):e0119156.
145. Seney FD Jr, Federgreen WR, Stein H, Kashgarian M. A review of nephrotic syndrome associated with chronic lymphocytic leukemia. *Arch Intern Med.* 1986;146(1):137–141.
146. Schneider R, Lugassy G, Schlesinger M, Kopolovic J, Yagil Y. Fibrillar glomerulopathy associated with chronic lymphocytic leukaemia. *Nephrol Dial Transplant.* 1996;11(7):1352–1355.
147. Korbet SM, Schwartz MM, Rosenberg BF, Sibley RK, Lewis EJ. Immunotactoid glomerulopathy. *Medicine (Baltimore).* 1985;64(4):228–243.
148. Touchard G, Bauwens M, Goujon JM, et al. Glomerulonephritis with organized microtubular monoclonal immunoglobulin deposits. In: Grunfeld JP, Bach JF, Kreis H, Maxwell MH, eds. *Advances in Nephrology.* Vol 23. St Louis: Mosby Yearbook; 1994:149–175.
149. Majumdar G. Unremitting severe autoimmune haemolytic anaemia as a presenting feature of Hodgkin's disease with minimum tumour load. *Leuk Lymphoma.* 1995;20(1–2):169–172.
150. Bjorkholm M, Holm G, Merk K. Cyclic autoimmune hemolytic anemia as a presenting manifestation of splenic Hodgkin's disease. *Cancer.* 1982;49(8):1702–1704.
151. Johnston PG, Ruscetti FW, Connaghan DG, Sullivan FJ, Longo DL. Transient reversal of bone marrow aplasia associated with lymphocyte depleted Hodgkin's disease after combination chemotherapy. *Am J Hematol.* 1991;38(1):54–60.
152. Levine AM, Thornton P, Forman SJ, et al. Positive Coombs test in Hodgkin's disease: significance and implications. *Blood.* 1980;55(4):607–611.
153. Shoho AR, Go RS, Tefferi A. 22 year old woman with severe microcytic anemia. *Mayo Clin Proc.* 2000;75(8):861–864.
154. Fahey JL, Rahbar S, Farbstein MJ, Forman SJ, Blume KG, Beutler E. Microcytosis in Hodgkin disease associated with unbalanced globin chain synthesis. *Am J Hematol.* 1986;23(2):123–129.
155. Slease RB, Schumacher HR. Deficiency of coagulation factors VII and XII in a patient with Hodgkin's disease. *Arch Intern Med.* 1977;137(11):1633–1635.
156. Mintz U, Marshak G, Sawicka B, Amir J. Transient hypofibrinogenemia in a patient with advanced Hodgkin's disease. *Tumori.* 1975;61(5):447–450.
157. Girolami A, Clifton EE. Fibrinolysis and proteolysis in patients with lymphoma. *Arch Intern Med.* 1966;117(6):778–783.
158. Wenz B, Friedman G. Acquired factor VIII inhibitor in a patient with malignant lymphoma. *Am J Med Sci.* 1974;268(5):295–299.
159. John F. Seymour. Splenomegaly, eosinophilia and pruritis in Hodgkins disease or...? *Blood.* 1997;90(4):1719–1720.
160. Kojima H, Takei N, Mukai Y, et al. Hemophagocytic syndrome as the primary clinical symptom of Hodgkin's disease. *Ann Hematol.* 2003;82(1):53–56.
161. Dawson L, den Ottolander GJ, Kluijn PM, Leeksa O. Reactive hemophagocytic syndrome as a presenting feature of Hodgkin's disease. *Ann Hematol.* 2000;79(6):322–326.
162. Drakonaki EE, Bradley KM, Khan ZA, Patel C, Wilson DJ. Hypertrophic osteoarthropathy in a child due to thoracic Hodgkin's disease. *Skeletal Radiol.* 2012;41(8):1027–1028.
163. Ansari N, Qureshi A, Hall GW. Images in haematology. Hypertrophic pulmonary osteoarthropathy in mediastinal Hodgkin lymphoma in childhood. *Br J Haematol.* 2010;150(2):130.
164. Karadeniz C, Oguz A, Dalgic N. Hypertrophic osteoarthropathy and childhood Hodgkin disease. *Pediatr Hematol Oncol.* 2001;18(1):79–82.
165. Milionis HJ, Elisaf MS. Psoriasiform lesions as paraneoplastic manifestation in Hodgkin's disease. *Ann Oncol.* 1998;9(4):449–452.
166. Reeder CB, Connolly SM, Winkelmann RK. The evolution of Hodgkin's disease and necrobiotic xanthogranuloma syndrome. *Mayo Clin Proc.* 1991;66(12):1222–1224.





167. Ramon D, Jorda E, Molina I, et al. Follicular mucinosis and Hodgkin's disease. *Int J Dermatol*. 1992;31(11):791-792.
168. Stewart M, Smoller BR. Follicular mucinosis in Hodgkin's disease: a poor prognostic sign? *J Am Acad Dermatol*. 1991;24(5 pt 1):784-785.
169. Shelnitz LS, Paller AS. Hodgkin's disease manifesting as prurigo nodularis. *Pediatr Dermatol*. 1990;7(2):136-139.
170. Leimert JT, Corder MP, Skibba CA, Gingrich RD. Erythema annulare centrifugum and Hodgkin's disease: association with disease activity. *Arch Intern Med*. 1979;139(4):486-487.
171. Yaniv R, Shpielberg O, Shpiro D, Feinstein A, Ben-Bassat I. Erythema annulare centrifugum as the presenting sign of Hodgkin's disease. *Int J Dermatol*. 1993;32(1):59-61.
172. Potaznik D, Steinherz P. Multiple nevoid basal cell carcinoma syndrome and Hodgkin's disease. *Cancer*. 1984;53(12):2713-2715.
173. Noto G, Pravata G, Miceli S, Arico M. Granulomatous slack skin: report of a case associated with Hodgkin's disease and a review of the literature. *Br J Dermatol*. 1994;131(2):275-279.
174. Luckner GP, Steijlen PM. Acrokeratosis paraneoplastica (Bazex syndrome) occurring with acquired ichthyosis in Hodgkin's disease. *Br J Dermatol*. 1995;133(2):322-325.
175. Shatin H. Ichthyosiform atrophy of the skin in Hodgkin's disease. *Arch Dermatol*. 1969;99(2):247-248.
176. Ronchese F, Gates DC. Ichthyosiform atrophy of the skin in Hodgkin's disease. *N Engl J Med*. 1956;255(6):287-289.
177. Simon S, Azevedo SJ, Byrnes JJ. Erythema nodosum heralding recurrent Hodgkin's disease. *Cancer*. 1985;56(6):1470-1472.
178. Sparsa A, Liozon E, Boulinguez S, et al. Generalized eczema craquelé as a presenting feature of systemic lymphoma: report of seven cases. *Acta Derm Venereol*. 2005;85(4):333-336.
179. Mlczoch L, Attarbaschi A, Dworzak M, Gadner H, Mann G. Alopecia areata and multifocal bone involvement in a young adult with Hodgkin's disease. *Leuk Lymphoma*. 2005;46(4):623-627.
180. Sacks EL, Donaldson SS, Gordon J, Dorfman RF. Epithelioid granulomas associated with Hodgkin's disease: clinical correlations in 55 previously untreated patients. *Cancer*. 1978;41(2):562-567.
181. Stadie V, Marsch WC. Itching attacks with generalized hyperhidrosis as initial symptoms of Hodgkin's disease. *J Eur Acad Dermatol Venereol*. 2003;17(5):559-561.
182. Wiener V, Honnorat J, Pandolfo M, Kentos A, Manto MU. Myorhythmia associated with Hodgkin's lymphoma. *J Neurol*. 2003;250(11):1382-1384.
183. Benisovich V, Papadopoulos E, Amorosi EL, Zucker-Franklin D, Silber R. The association of progressive, atrophying, chronic, granulomatous dermohypodermatitis with Hodgkin's disease. *Cancer*. 1988;62(11):2425-2429.
184. Walters EG, Tavare JM, Denton RM, Walters G. Hypoglycaemia due to an insulin-receptor antibody in Hodgkin's disease. *Lancet*. 1987;1(8527):241-243.
185. Nadiminti Y, Wang JC, Chou SY, Pineles E, Tobin MS. Lactic acidosis associated with Hodgkin's disease: response to chemotherapy. *N Engl J Med*. 1980;303(1):15-17.
186. Bennett JS, Bond J, Singer I, Gottlieb AJ. Hypouricemia in Hodgkin's disease. *Ann Intern Med*. 1972;76(5):751-756.
187. Gabrys K, Kaiser A, Hirmle Z. Hypouricemia in Hodgkin's disease. *Pol Arch Med Wewn*. 1978;60(1):67-70.
188. Zamkoff K, Kaplan M, Gottlieb AJ. Hypouricemia in Hodgkin's disease. Relation to extent of disease. *NY State J Med*. 1978;78(7):1047-1049.
189. Singh AP, Charan VD, Desai N, Choudhry VP. Hypertension as a paraneoplastic phenomenon in childhood Hodgkin's disease. *Leuk Lymphoma*. 1993;11(3-4):315-317.
190. Eliakim R, Vertman E, Shinhar E. Syndrome of inappropriate secretion of antidiuretic hormone in Hodgkin's disease. *Am J Med Sci*. 1986;291(2):126-127.
191. Taillandier J, Manigand G, Dusein P. Inappropriate antidiuresis in Hodgkin's disease. *Presse Med*. 1985;14(18):1037.
192. Chang JC, Gross HM. Neoplastic fever responds to the treatment of an adequate dose of naproxen. *J Clin Oncol*. 1985;3(4):552-558.
193. Gobbi PG, Pieresca C, Ricciardi L, et al. Night sweats in Hodgkin's disease. A manifestation of preceding minor febrile pulses. *Cancer*. 1990;65(9):2074-2077.
194. Rieke JW, Donaldson SS, Horning SJ. Hypercalcemia and vitamin D metabolism in Hodgkin's disease. Is there an underlying immunoregulatory relationship? *Cancer*. 1989;63(9):1700-1707.
195. Amezyane T, Lecoules S, Bordier L, et al. Humoral hypercalcemia revealing a malignant non Hodgkin lymphoma. *Ann Endocrinol (Paris)*. 2008;69(1):58-62.
196. Hennemann HH, Hastka J, Lengfelder E, Pfeister P, Bonatz K. Hypercalcemias in chronic lymphatic leukemias and other non-Hodgkin's lymphomas. *Klin Wochenschr*. 1987;65(16):791-797.
197. Ganzoni A, Trachsler M. A case of chronic lymphatic leukemia and Hodgkin's lymphogranuloma malignum with hypercalcemic metabolic disorders. *Med Lab (Stuttg)*. 1964;17:56-62.
198. Mulatero P, Rabbia F, Veglio F. Paraneoplastic hyperaldosteronism associated with non-Hodgkin's lymphoma. *N Engl J Med*. 2001;344(20):1558-1559.
199. Abedi SH, Ghassami M, Molaei M, Mohsenifar Z, Mohammad Alizadeh AH. Secondary sclerosing cholangitis and Hodgkin's lymphoma. *Clin Med Insights Case Rep*. 2015;8:83-87.
200. Kosmidou IS, Aggarwal A, Ross JJ, Worthington MG. Hodgkin's disease with fulminant non-alcoholic steatohepatitis. *Dig Liver Dis*. 2004;36(10):691-693.
201. Dourakis SP, Tzemanakis E, Deutsch M, Kafiri G, Hadziyannis SJ. Fulminant hepatic failure as a presenting paraneoplastic manifestation of Hodgkin's disease. *Eur J Gastroenterol Hepatol*. 1999;11(9):1055-1058.
202. Kleger A, Bommer M, Kunze M, et al. First reported case of disease: peliosis hepatis as cardinal symptom of Hodgkin's lymphoma. *Oncologist*. 2009;14(11):1088-1094.
203. Corpa MV, Bacchi MM, Bacchi CE, Coelho KI. Peliosis hepatis associated with lymphoplasmacytic lymphoma: an autopsy case report. *Arch Pathol Lab Med*. 2004;128(11):1283-1285.
204. Abdelli N, Bouhnik Y, Lavergne-Slove A, Messing B, Galian A, Rambaud JC. Peliosis hepatitis during intestinal lymphomatous polyposis treated with chemotherapy and radiotherapy. Regression after antibiotic therapy. *Gastroenterol Clin Biol*. 1995;19(5):537-541.
205. Bhaskar KV, Joshi K, Banerjee CK, Rao RK, Verma SC. Peliosis hepatis in Hodgkin's disease: an infrequent association. *Am J Gastroenterol*. 1990;85(5):628-629.
206. Lachance DH, O'Neill BP, Harper CM Jr, Banks PM, Cascino TL. Paraneoplastic brachial plexopathy in a patient with Hodgkin's disease. *Mayo Clin Proc*. 1991;66(1):97-101.
207. Mulligan MJ, Vasu R, Grossi CE, et al. Neoplastic meningitis with eosinophilic pleocytosis in Hodgkin's disease: a case with cerebellar dysfunction and a review of the literature. *Am J Med Sci*. 1988;296(5):322-326.
208. Levy Y, Barron SA, Shahin S, Haim N, Brook JG. Sympathetic dysautonomia as a remote effect of Hodgkin's lymphoma. *Am J Med*. 1993;95(3):340.
209. Hertz M, Solomon A, Aghai E. 'Ivory vertebra' in Hodgkin's disease. Restoration of trabecular pattern after therapy. *JAMA*. 1977;238(22):2402.