

PERSPECTIVES

Osteonecrosis of the Jaw: Recent Clinical and Preclinical Advances

Matthew R. Allen¹ and Salvatore L. Ruggiero²

¹Department of Anatomy and Cell Biology, Indiana University School of Medicine, Indianapolis, Indiana, USA

²New York Center for Orthognathic and Maxillary Surgery, Lake Success, New York and Department of Oral and Maxillofacial Surgery, School of Dental Medicine, SUNY at Stony Brook, Stony Brook, New York, USA

Abstract

Although first described nearly seven years ago and despite receiving a significant amount of attention in the scientific and lay community, it has only been in the past few years that significant progress toward understanding osteonecrosis of the jaw (ONJ) has occurred. The purpose of this *Perspective* is to update recent clinical aspects related to defining and treating ONJ and also significant preclinical advances in animal model development. Although we still have much to learn about this condition, progress over the past few years is encouraging and certainly headed in the right direction. *IBMS BoneKEy*. 2011 March;8(3):141-153.

©2011 International Bone & Mineral Society

Defining the Clinical Presentation of Osteonecrosis of the Jaw

Since the first descriptions of bone necrosis in patients receiving bisphosphonate therapy in 2004 (1;2) there have been multiple retrospective, prospective and case-controlled studies that have served to adequately characterize the clinical presentation, associated risk factors and treatment of this new complication. As our understanding of this disease process has improved so has our ability to diagnose and treat this condition.

The existing literature still does not support a cause and effect relationship between bisphosphonate exposure and jaw necrosis. However, epidemiologic studies have established a strong association between IV bisphosphonates and osteonecrosis of the jaw (ONJ) in the setting of malignant disease. This is based on a positive correlation between bisphosphonate potency and duration of therapy in relation to the presentation of ONJ (3). The same level of support does not exist for oral bisphosphonates or IV bisphosphonates

used in patients with osteoporosis or other non-malignant conditions.

The diagnostic criteria for ONJ have remained unchanged since it was first defined in 2006. The tenants of the diagnosis include: 1) an exposure history to bisphosphonates, 2) exposed bone within the oral cavity, and 3) no history of prior radiation therapy to the jaws. However, the emergence of jaw necrosis in bisphosphonate-naive patients receiving RANKL inhibitors (4-6) may necessitate a modification of these criteria in the near future. The finding of exposed, necrotic bone remains the hallmark of the diagnosis and therefore the physical examination is the most effective method of establishing the diagnosis of jaw necrosis (Fig. 1). A clinical staging system developed by Ruggiero *et al.* (7) and adopted by the American Association of Oral and Maxillofacial Surgeons (AAOMS) in 2006 (8) has served to categorize patients with ONJ, direct rational treatment guidelines, and collect data to assess the prognosis and treatment outcome in patients who have used either IV or oral bisphosphonates. Since the

publication of these treatment guidelines, reports of non-specific signs and symptoms such as pain, abscess formation, altered sensory function or osteosclerosis have emerged in patients with a bisphosphonate exposure history but no clinical evidence of necrosis. In an effort to determine whether or not these findings represent a precursor

for clinical disease, the recently updated AAOMS position paper has included these patients in a new Stage 0 category (9) (Table 1). The degree to which these patients with Stage 0 disease progress to overt ONJ remains to be determined and represents an important area for future work.

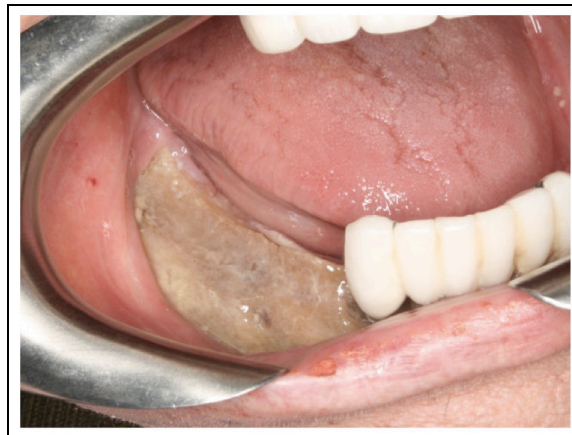

Fig. 1. Exposed, necrotic right mandible in a patient with breast cancer and a history of monthly intravenous bisphosphonate exposure.

Table 1. Clinical staging criteria for ONJ.

Category	Description
At risk	No apparent exposed/necrotic bone in patients who have been treated with either oral or IV bisphosphonates
Stage 0	Non-specific clinical findings and symptoms such as jaw pain or osteosclerosis but no clinical evidence of exposed bone
Stage 1	Exposed/necrotic bone in patients who are asymptomatic and have no evidence of infection
Stage 2	Exposed/necrotic bone associated with infection as evidenced by pain and erythema in the region of the exposed bone with or without purulent drainage
Stage 3	Exposed/necrotic bone in patients with pain, infection, and one or more of the following: pathologic fracture, extra-oral fistula, or osteolysis extending to the inferior border or sinus floor

Multiple risk factors including drug-related issues (potency and duration of exposure), local risk factors (dentoalveolar surgery), local anatomy, concomitant oral and systemic disease, demographic factors and genetic factors have all been associated with ONJ. However, only three of these risk factors have remained constant throughout most clinical studies. In the majority of ONJ cases reported to date, recent dentoalveolar trauma was the most prevalent and consistent risk factor (10-12). Patients with a history of inflammatory dental disease, e.g., periodontal and dental abscesses, are at a seven-fold increased risk for developing

ONJ (13). The duration of bisphosphonate therapy also appears strongly related to the likelihood of developing necrosis, with longer treatment regimens associated with a greater risk of developing disease (12;13). In addition, the more potent intravenous bisphosphonates that are administered on a monthly schedule such as zoledronic acid and pamidronate are significantly more problematic as compared with other preparations.

Efforts to establish risk assessment by measuring fluctuations in bone turnover markers are problematic and remain

controversial (14-18). The rationale for this approach is based on the knowledge that markers for bone remodeling will increase within months following withdrawal of oral bisphosphonate medications, thereby suggesting that osteoclastic function and bone remodeling were normalizing (19;20). Recent data show that IV bisphosphonates do not have a similar return toward baseline even three years after a single injection (21), suggesting the dynamics of resorption recovery differ by the route of administration and/or the specific bisphosphonate. It is important to also note that these markers are a reflection of total bone turnover throughout the entire skeleton and are not specific to the maxilla or mandible where it is suspected that the bone turnover rate may be more severely depressed from prolonged bisphosphonate exposure. From a more practical perspective, using bone turnover markers to estimate the level of bone turnover suppression is only meaningful when compared to baseline, pre-treatment levels and these are rarely obtained in clinical practice. In addition, using bone resorption marker levels to assess ONJ risk can be misleading for the small cohort of patients that develop osteoporosis despite normal baseline levels of bone resorption markers.

The radiographic features of ONJ remain relatively non-specific. In fact, plain film

radiography does not typically demonstrate any abnormality in the early stages of the disease due to the limited degree of decalcification that is present. However, findings on plain film imaging such as localized or diffuse osteosclerosis or a thickening of the lamina dura (components of Stage 0) may be predictors for future sites of exposed, necrotic bone. The findings on computed tomography (CT) are also non-specific but this modality is significantly more sensitive to changes in bone mineralization and therefore is more likely to demonstrate areas of focal sclerosis, thickened lamina dura, early sequestrum formation and the presence of reactive periosteal bone (Fig. 2). The CT images have also proved to be more accurate delineating the extent of disease, which is very helpful for surgical treatment planning (22;23). The utility of nuclear bone scanning in patients at risk of ONJ has received growing attention following reports of increased tracer uptake in regions of the jaws that subsequently developed necrosis (24;25). While nuclear imaging has limited value in patients with existing disease, its usefulness as a predictive tool in those patients with pre-clinical disease (Stage 0) appears to have some level of potential benefit and therefore requires continued evaluation.

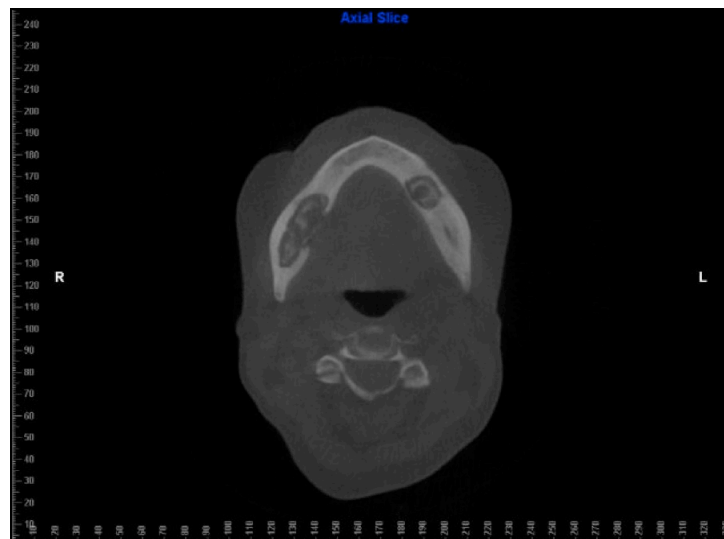


Fig. 2. Axial CT scan of a patient with Stage 3 ONJ exhibiting extensive osteosclerosis and distinct regions of sequestrum formation in the right and left mandible.

Advancements in Treating ONJ

The management of patients with ONJ remains very challenging since surgical and medical interventions may not eradicate this process. The goal of treatment for patients at risk of developing ONJ or who have active disease is to preserve the quality of life by controlling pain, managing infection and preventing the development of new areas of necrosis. This has to be balanced with the oncologic management of the patient with osteolytic metastases and the risk of pathologic fracture in the osteoporotic patient.

The treatment approach for patients with Stage 1 disease is primarily non-surgical since these patients are not infected or symptomatic. In most Stage 1 patients, the exposed bone will eventually mature into a defined sequestrum that can be easily removed. Since infection and pain are typical for patients with Stage 2 disease, these patients will benefit from local and systemic antibiotic therapy. As with those with Stage 1 disease, those with Stage 2 disease will likely develop sequestra that in most cases can be managed with local debridement. In patients with Stage 3 disease, the extensive nature of the necrosis and infection usually dictate early surgical treatment (segmental resection or marginal resection) for control of the infection and pain. In some institutions, early surgical treatment, regardless of disease stage, was associated with a good level of cure and disease control, suggesting that surgical treatment may play a larger role in managing this complication in the near future (26-28).

Nuances in surgical and non-surgical treatment have recently emerged and may be of value. The use of hyperbaric oxygen therapy (HBO) as an adjunct to non-surgical treatment or surgical treatment is in progress at several institutions. The preliminary results from a pilot study report some improvement in wound healing and pain scores but its routine use as an effective adjunct or primary treatment modality requires further evidenced-based review (29). The use of platelet-rich plasma as an adjunct to local resection and primary

closure was reported in a total of 5 cases at 2 separate institutions (30;31). In all instances there was complete wound healing and resolution of pain. However, the small number of cases that were reported and the lack of controls mandate that further studies be conducted prior to utilizing this technique on a large scale. In three separate case reports, the utilization of systemic low-dose parathyroid hormone (PTH), an anabolic bone hormone, was successful in resolving an area of necrosis when other modalities of treatment had failed (32-34). In a recent prospective, placebo-controlled study of 40 patients, low-dose systemic PTH in conjunction with vitamin D and oral calcium was associated with greater resolution of periodontal bone defects and accelerated intra-oral osseous healing (35). This report does not have direct relevance to ONJ yet it does highlight the fact that PTH has clear anabolic effects on craniofacial bones and, more specifically, bone healing. Although PTH is contraindicated in patients with osteolytic bone metastases, this clinical trial showing positive effects on oral healing combined with the case reports on ONJ healing may have real applicability for ONJ cases in the non-cancer setting.

In those patients who are at risk of developing ONJ, adherence to risk reduction protocols has resulted in a decreased incidence of this complication at certain institutions (36). Implementation of a detailed dental assessment and the avoidance of dentoalveolar surgery during treatment with zoledronic acid resulted in a 5-fold reduction of osteonecrosis (37). In those instances where ONJ has developed, instituting stage-specific treatment protocols has resulted in a good level of disease and symptom control in a large majority of cases (38).

Preclinical Advances – The Quest for an Animal Model

The benefits of an animal model that recapitulates the major clinical features of ONJ has been repeatedly acknowledged since soon after the identification of ONJ (39-41). Over the past two years significant progress has been made with over a dozen papers published in which potential animal

models of ONJ have been described in mice, rats, and dogs. These studies represent a step in the right direction, although it remains unclear which, if any, represent the most useful and representative model. Although comparing

and contrasting the models is difficult because of differences in study designs, we have summarized below what we feel are the major strength/limitations of the models published to date (Table 2).

Table 2. Summary of animal models of ONJ.

<p><u>Mouse (3 studies)</u></p> <ul style="list-style-type: none">• 1 of 3 studies report exposed bone; 2 of 3 report necrotic bone matrix.• Exposed and necrotic bone routinely noted in animals not treated with bisphosphonates albeit at lower rates than in animals treated with bisphosphonates.• Encouraging preliminary studies aimed at potential treatments.
<p><u>Rat (8 studies)</u></p> <ul style="list-style-type: none">• 6 of 8 studies report exposed bone.• All studies reporting exposed bone following extraction either extracted multiple teeth or combined extraction with an enlargement of the original defect.• One report of exposed bone with only bisphosphonate treatment (no dental intervention or concomitant treatment).
<p><u>Dog (2 studies)</u></p> <ul style="list-style-type: none">• Necrotic bone matrix in the absence of dental intervention; no such matrix necrosis in untreated animals.• Exposed bone and sequestrum formation in a small percentage of animals treated with zoledronate combined with dental extraction.

Mouse Models of ONJ

Three published reports in mice have focused on ONJ. Two separate reports by the same laboratory group have presented some of the most detailed analyses and results as well as potential insight into the pathology of ONJ (42;43). In these studies, skeletally immature mice were treated with zoledronate (ZOL) with or without concomitant dexamethasone (DEX) and/or docetaxel and then subjected to extraction of the first maxillary molar. In one study, bone matrix necrosis, defined as bone near the extraction site that contains empty lacunae, is shown to be most prevalent in animals treated with ZOL + DEX although regions were also observed in untreated and DEX-only animals (42) (Fig. 3). The addition of docetaxel exacerbates the amount of necrotic bone matrix (both with and without ZOL) and also produces a soft tissue phenotype (lack of mucosal coverage) in some animals. Somewhat surprisingly, the

model did not result in exposed bone – a clinical hallmark and diagnosis criterion of ONJ. In a follow-up study by the same group, the authors observed exposed bone in 11% of controls, 17% of ZOL, and 50% of DEX or DEX+ZOL two weeks post-extraction (43) (Fig. 3). By seven weeks post-extraction all control and DEX animals had healed extraction sites while 10% of ZOL and 30% of ZOL + DEX remained unhealed. This second study also began to investigate potential preventative measures for ONJ – showing that suppression of immune function increased the number of animals with exposed bone and that treatment with either adaptive regulatory T cells, or mesenchymal stem cells, prevented any animals from having exposed bone at seven weeks post-extraction (43). In both studies, the presence of regions of exposed bone in untreated animals at the early time points raises some questions about the model, most notably whether the mouse is overly susceptible to developing necrotic

bone following dental surgery. While this could be viewed as an advantage in that it provides a nice study model, it remains unclear if this represents an important physiological difference compared to humans. Nonetheless, these studies represent a significant advance in the field and provide a foundation for future work to

explore the model in more detail. One other mouse experiment, by a separate group of researchers, had relatively short-term ZOL or etidronate treatment (11 days) and showed no effect of bisphosphonate on extraction site healing although assessment was made just five days post-extraction (44).

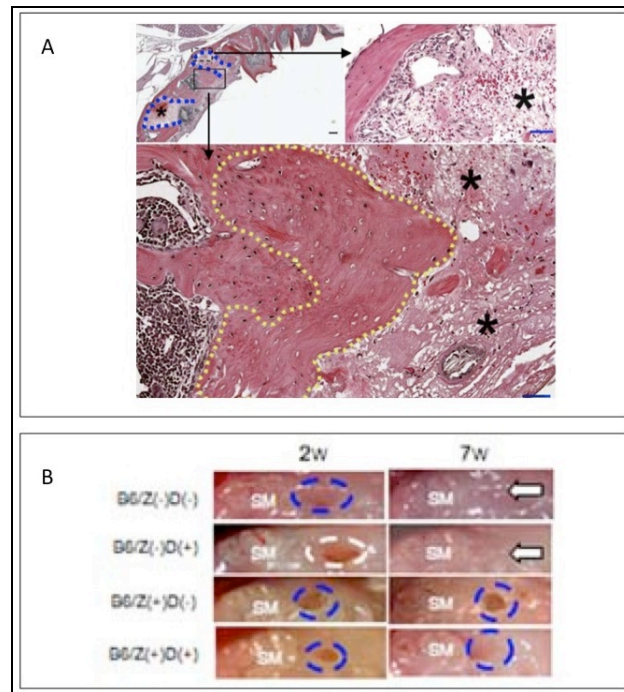


Fig. 3. Mouse models of ONJ. (A) One day following extraction of a single molar in the maxilla (depicted by blue box in upper left panel); regions of bone matrix void of osteocytes (demarcated in yellow) are defined as necrotic. This is a commonly employed criteria for defining osteonecrosis although in most cases it is only semi-quantitative (reprinted with permission from the American Society for Investigative Pathology (42)). (B) Following extraction of a molar in the maxilla, exposed bone/non-healed sockets are more prominent in animals treated with bisphosphonates (reproduced with permission from (43)).

Rat Models of ONJ

The earliest report of exposed bone associated with bisphosphonate treatment in any animal model is from Gotcher and Jee who, in 1981, showed that treatment of weanling rats with high doses of clodronate resulted in some animals developing protruding trabeculae through the soft tissue of the oral cavity (45). These rats were genetically susceptible to development of periodontal disease yet were not subjected to dental surgery.

More recently, eight additional publications have focused on rats as a model for ONJ. While the rat is the most utilized model at

this point, the conclusions drawn from the papers vary significantly. Six of the eight papers have noted exposed bone although, in general, they have not employed the most rigorous quantitative evaluation. In most studies, a high percentage of animals have exposed bone (60-100%) while a small number of control animals also have exposed bone. This again raises the question of whether rats (or rodents in general) are more susceptible to having exposed bone following extraction even in untreated conditions. Additionally, many of the studies note empty osteocyte lacunae and suggest this to be evidence that the tissue is necrotic. Given that there is often no quantification of the amount of empty

lacunae, this statement is difficult to interpret. Certainly, some percentage of osteocyte lacunae will be empty in any animal at any bone site.

One potentially important difference between the rat studies that do and do not report exposed bone post-extraction is that those studies that show exposed bone all have extracted multiple teeth. In a precedent likely set from the early work of Sonis *et al.* (46), all molars are often extracted from the right or left maxilla in these rat studies (47-49) (Fig. 4). This represents a significant surgical insult, quite unlike what is performed in most clinical situations where ONJ develops. In the one paper where exposed bone developed after a single tooth extraction, the extraction was coupled with an additional expansion of the socket to 4

mm, again a dramatic surgical insult (50). It will be important in future studies using rats to determine if the size of the defect plays a role in whether or not ONJ will develop. There also exists one report in rats showing exposed bone in animals treated with either ZOL or pamidronate in the absence of dental extraction (51). These rats were treated for 6 or 8 weeks with moderate doses of bisphosphonate with a select number (1-2 in the treated groups) developing rather severe bone and soft tissue necrosis in the jaw. This represents the lone case in the literature where such dramatic tissue destruction has been noted in the absence of any oral surgery. Given the limited numbers of animals that developed such necrosis it is unclear if there were other confounding factors in these particular animals.

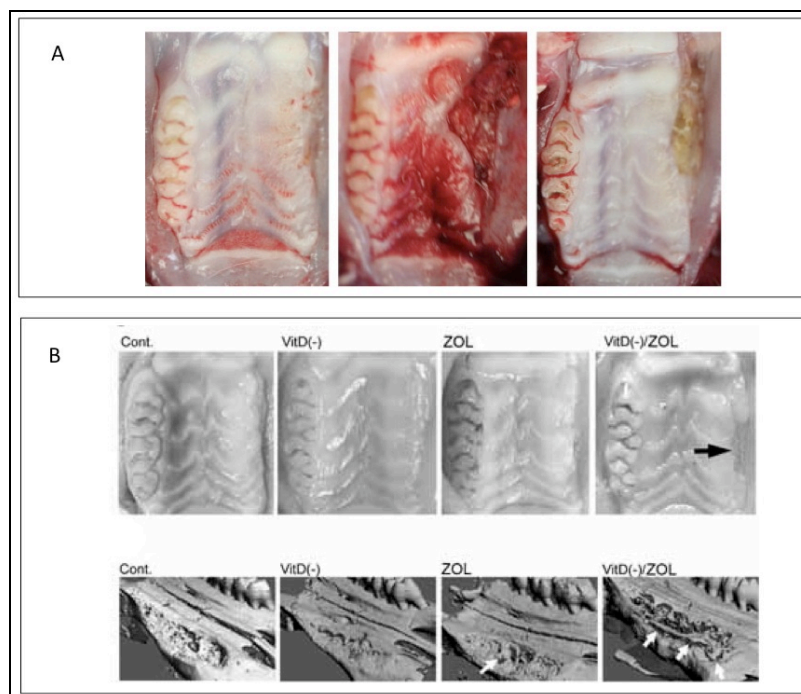


Fig. 4. Rat models of ONJ. Following extraction of all molars of the left maxillary, significant soft tissue destruction and exposed bone can be noted in bisphosphonate-treated animals. Using CT, regions of detached bone matrix have been observed (reproduced with permission from (46) (A) and (47) (B)).

A recent paper documenting ONJ in a rat model was focused on the interaction between bisphosphonates and vitamin D (VitD) deficiency (47). As a significant percentage of the U.S. population is VitD-deficient, the role of VitD in ONJ is not entirely clear. However, this paper provides two valuable additions to the ONJ literature,

including a nice array of different assessments of necrotic bone as well as an interesting interpretation regarding the role of tooth fracture on formation of sequestra. In this study, two weeks following the extraction of all left maxillary molars, the prevalence of ONJ in the VitD(-)/ZOL group was 66.7% and 14.3% in ZOL, while it was

0% in control and Vit(-). Interestingly, bone sequestra were noted in all groups although the highest number of affected animals were in the VitD(-)/ZOL group. The authors noted that sequestra often had the shape of normal alveolar bone and suggested they may have been the result of fracturing the bone at the time of extraction. This raises an interesting point that is rarely addressed in any of these animal studies. The trauma associated with extracting otherwise healthy teeth can be substantial. Upwards of 25% of the extractions in one report resulted in the tooth fracturing (52). If/how fracturing the tooth, or the surrounding bone, plays into healing of the site remains unclear but should be explored in future work.

Dog Models of ONJ

Two separate published reports have documented evidence of osteonecrosis in dogs. In an early experiment where animals were treated for 3 years with oral alendronate (ALN) and were not subjected to dental surgery, regions of matrix necrosis were evident in about 30% of ALN-treated animals and were notably absent in all controls (53). This was not exposed bone but instead large areas (> 500 μm x 500 μm

in size) within the matrix that were devoid of osteocytes and patent canaliculi determined by basic fuchsin staining and histological analysis (Fig. 5). Similar results were later noted in animals treated for one year with oral ALN (54). In experiments specifically aimed at understanding the interaction between dental extraction and bisphosphonates in dogs, 1 out of 6 animals treated with ZOL developed exposed bone post-extraction that eventually led to the formation of a sequestrum (Fig. 5). Assessment of the sequestrum with micro-CT and histology showed that it had features consistent with those reported in humans with ONJ (55). In this extraction study, 50% of the 12 extractions in the control group (right and left premolars were each extracted at two different time points) had at least one root fracture (there are two roots to each premolar). In the ZOL group only 1 of 12 animals had a root fracture. In this study, sockets that contained roots that fractured were excluded from the study and the one animal that developed exposed bone did not have any root fractures. These data suggest that, at least in the large animal model, the fracturing of teeth during extraction is not itself a cause of necrosis.

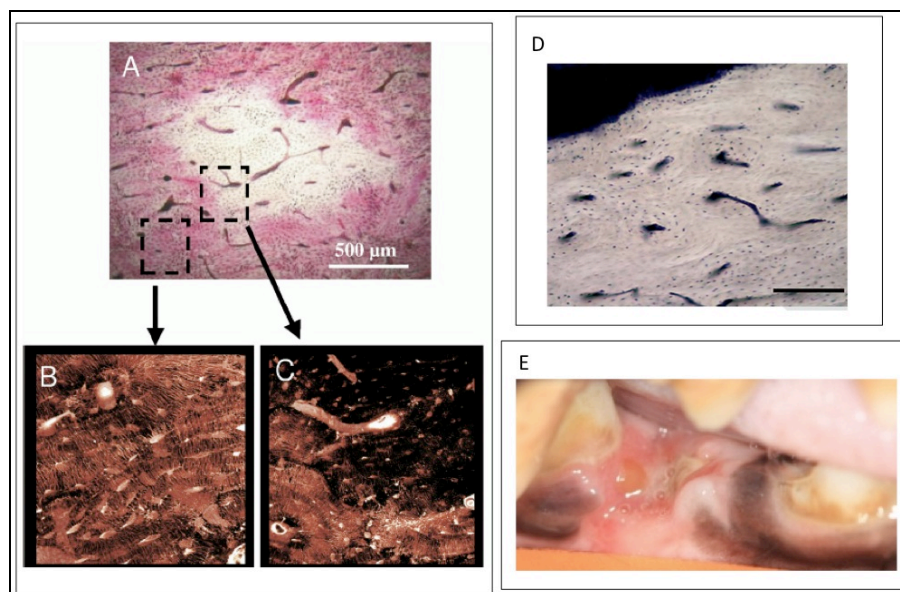


Fig. 5. Dog model of ONJ. Treatment with bisphosphonates results in accumulation of necrotic bone matrix. Brightfield and confocal imaging of basic fuchsin-stained tissue reveals a lack of patent canaliculi in discrete regions (A-C; reproduced with permission from (53)) while non-viable osteocytes can also be observed using lactate dehydrogenase histochemistry (D; reproduced with permission from S. Karger AG, Basel (56)). Combining ZOL and dental extraction produced exposed bone in one of six animals (E; reproduced with permission from (55)).

Continuing to Move Forward

Although ONJ has been recognized as a clinical entity for almost 7 years, our understanding of the condition remains unacceptably low. Significant progress has occurred in the past few years and likely will accelerate in the years to come only if more focused clinical studies are undertaken and if animal models, either those described above or others, are studied in detail. This is even more urgent given the recent findings of ONJ in patients treated with other potent anti-remodeling agents (denosumab). The overwhelmingly positive benefits of anti-remodeling agents both in the osteoporosis and oncology settings are clear and thus the key for minimizing the impact of ONJ will be to define those patients most at risk, find methods of early detection, and then develop ways to prevent progression toward developing exposed bone or treat those who do develop exposed bone.

Conflict of Interest: Dr. Ruggiero reports that he is a consultant for Amgen. Dr. Allen reports that he is a consultant for Warner Chilcott.

Peer Review: This article has been peer-reviewed.

References

1. Ruggiero SL, Mehrotra B, Rosenberg TJ, Engroff SL. Osteonecrosis of the jaws associated with the use of bisphosphonates: a review of 63 cases. *J Oral Maxillofac Surg.* 2004 May;62(5):527-34.
2. Marx RE. Pamidronate (Aredia) and zoledronate (Zometa) induced avascular necrosis of the jaws: a growing epidemic. *J Oral Maxillofac Surg.* 2003 Sep;61(9):1115-7.
3. Dodson TB. Intravenous bisphosphonate therapy and bisphosphonate-related osteonecrosis of the jaws. *J Oral Maxillofac Surg.* 2009 May;67(5 Suppl):44-52.
4. Aghaloo TL, Felsenfeld AL, Tetradis S. Osteonecrosis of the jaw in a patient on denosumab. *J Oral Maxillofac Surg.* 2010 May;68(5):959-63.
5. Stopeck A, Body JJ, Fujiwara Y, Lipton A, Steger GG, Viniegra M, Fan M, Braun A, Dansey R, Jun S. Denosumab versus zoledronic acid for the treatment of breast cancer patients with bone metastases: results of a randomized phase 3 study. *Eur J Cancer Suppl.* 2009;7(3):2-3.
6. Taylor KH, Middlefell LS, Mizen KD. Osteonecrosis of the jaws induced by anti-RANK ligand therapy. *Br J Oral Maxillofac Surg.* 2010 Apr;48(3):221-3.
7. Ruggiero SL, Fantasia J, Carlson E. Bisphosphonate-related osteonecrosis of the jaw: background and guidelines for diagnosis, staging and management. *Oral Surg Oral Med Oral Pathol Oral Radiol Endod.* 2006 Oct;102(4):433-41.
8. Advisory Task Force on Bisphosphonate-Related Osteonecrosis of the Jaws, American Association of Oral and Maxillofacial Surgeons. American Association of Oral and Maxillofacial Surgeons position paper on bisphosphonate-related osteonecrosis of the jaws. *J Oral Maxillofac Surg.* 2007 Mar;65(3):369-76.
9. Ruggiero SL, Dodson TB, Assael LA, Landesberg R, Marx RE, Mehrotra B; American Association of Oral and Maxillofacial Surgeons. American Association of Oral and Maxillofacial Surgeons position paper on bisphosphonate-related osteonecrosis of the jaws--2009 update. *J Oral Maxillofac Surg.* 2009 May;67(5 Suppl):2-12.
10. Marx RE, Sawatari Y, Fortin M, Broumand V. Bisphosphonate-induced exposed bone (osteonecrosis/osteopetrosis) of the jaws: risk factors, recognition, prevention, and treatment. *J Oral Maxillofac Surg.* 2005 Nov;63(11):1567-75.
11. Durie BG, Katz M, Crowley J. Osteonecrosis of the jaw and bisphosphonates. *N Engl J Med.* 2005 Jul 7;353(1):99-102; discussion 99-102.

12. Badros A, Weikel D, Salama A, Goloubeva O, Schneider A, Rapoport A, Fenton R, Gahres N, Sausville E, Ord R, Meiller T. Osteonecrosis of the jaw in multiple myeloma patients: clinical features and risk factors. *J Clin Oncol*. 2006 Feb 20;24(6):945-52.
13. Hoff AO, Toth BB, Altundag K, Johnson MM, Warneke CL, Hu M, Nooka A, Sayegh G, Guarneri V, Desrouleaux K, Cui J, Adamus A, Gagel RF, Hortobagyi GN. Frequency and risk factors associated with osteonecrosis of the jaw in cancer patients treated with intravenous bisphosphonates. *J Bone Miner Res*. 2008 Jun;23(6):826-36.
14. Bagan JV, Jiménez Y, Gómez D, Sirera R, Poveda R, Scully C. Collagen telopeptide (serum CTX) and its relationship with the size and number of lesions in osteonecrosis of the jaws in cancer patients on intravenous bisphosphonates. *Oral Oncol*. 2008 Nov;44(11):1088-9.
15. Kunchur R, Need A, Hughes T, Goss A. Clinical investigation of C-terminal cross-linking telopeptide test in prevention and management of bisphosphonate-associated osteonecrosis of the jaws. *J Oral Maxillofac Surg*. 2009 Jun;67(6):1167-73.
16. Kwon YD, Kim DY, Ohe JY, Yoo JY, Walter C. Correlation between serum C-terminal cross-linking telopeptide of type I collagen and staging of oral bisphosphonate-related osteonecrosis of the jaws. *J Oral Maxillofac Surg*. 2009 Dec;67(12):2644-8.
17. Lehrer S, Montazem A, Ramanathan L, Pessin-Minsley M, Pfail J, Stock RG, Kogan R. Normal serum bone markers in bisphosphonate-induced osteonecrosis of the jaws. *Oral Surg Oral Med Oral Pathol Oral Radiol Endod*. 2008 Sep;106(3):389-91.
18. Marx RE, Cillo JE Jr, Ulloa JJ. Oral bisphosphonate-induced osteonecrosis: risk factors, prediction of risk using serum CTX testing, prevention, and treatment. *J Oral Maxillofac Surg*. 2007 Dec;65(12):2397-410.
19. Rosen HN, Moses AC, Garber J, Iloputaife ID, Ross DS, Lee SL, Greenspan SL. Serum CTX: a new marker of bone resorption that shows treatment effect more often than other markers because of low coefficient of variability and large changes with bisphosphonate therapy. *Calcif Tissue Int*. 2000 Feb;66(2):100-3.
20. Rosen HN, Moses AC, Garber J, Ross DS, Lee SL, Greenspan SL. Utility of biochemical markers of bone turnover in the follow-up of patients treated with bisphosphonates. *Calcif Tissue Int*. 1998 Nov;63(5):363-8.
21. Grey A, Bolland M, Wattie D, Horne A, Gamble G, Reid IR. Prolonged antiresorptive activity of zoledronate: a randomized, controlled trial. *J Bone Miner Res*. 2010 Oct;25(10):2251-5.
22. Treister NS, Friedland B, Woo SB. Use of cone-beam computerized tomography for evaluation of bisphosphonate-associated osteonecrosis of the jaws. *Oral Surg Oral Med Oral Pathol Oral Radiol Endod*. 2010 May;109(5):753-64.
23. Arce K, Assael LA, Weissman JL, Markiewicz MR. Imaging findings in bisphosphonate-related osteonecrosis of jaws. *J Oral Maxillofac Surg*. 2009 May;67(5 Suppl):75-84.
24. Chiandussi S, Biasotto M, Dore F, Cavalli F, Cova MA, Di Lenarda R. Clinical and diagnostic imaging of bisphosphonate-associated osteonecrosis of the jaws. *Dentomaxillofac Radiol*. 2006 Jul;35(4):236-43.
25. O'Ryan FS, Khoury S, Liao W, Han MM, Hui RL, Baer D, Martin D, Liberty D, Lo JC. Intravenous bisphosphonate-related osteonecrosis of the jaw: bone scintigraphy as an early indicator. *J Oral Maxillofac Surg*. 2009 Jul;67(7):1363-72.

26. Carlson ER, Basile JD. The role of surgical resection in the management of bisphosphonate-related osteonecrosis of the jaws. *J Oral Maxillofac Surg.* 2009 May;67(5 Suppl):85-95.
27. Mücke T, Koschinski J, Deppe H, Wagenpfeil S, Pautke C, Mitchell DA, Wolff KD, Hölzle F. Outcome of treatment and parameters influencing recurrence in patients with bisphosphonate-related osteonecrosis of the jaws. *J Cancer Res Clin Oncol.* 2010 Oct 7. [Epub ahead of print]
28. Stockmann P, Vairaktaris E, Wehrhan F, Seiss M, Schwarz S, Spriewald B, Neukam FW, Nkenke E. Osteotomy and primary wound closure in bisphosphonate-associated osteonecrosis of the jaw: a prospective clinical study with 12 months follow-up. *Support Care Cancer.* 2010 Apr;18(4):449-60.
29. Freiberger JJ. Utility of hyperbaric oxygen in treatment of bisphosphonate-related osteonecrosis of the jaws. *J Oral Maxillofac Surg.* 2009 May;67(5 Suppl):96-106.
30. Curi MM, Cossolin GS, Koga DH, Araújo SR, Feher O, dos Santos MO, Zardetto C. Treatment of avascular osteonecrosis of the mandible in cancer patients with a history of bisphosphonate therapy by combining bone resection and autologous platelet-rich plasma: Report of 3 cases. *J Oral Maxillofac Surg.* 2007 Feb;65(2):349-55.
31. Lee CY, David T, Nishime M. Use of platelet-rich plasma in the management of oral bisphosphonate-associated osteonecrosis of the jaw: a report of 2 cases. *J Oral Implantol.* 2007;33(6):371-82.
32. Harper RP, Fung E. Resolution of bisphosphonate-associated osteonecrosis of the mandible: possible application for intermittent low-dose parathyroid hormone [rhPTH(1-34)]. *J Oral Maxillofac Surg.* 2007 Mar;65(3):573-80.
33. Lau AN, Adachi JD. Resolution of osteonecrosis of the jaw after teriparatide [recombinant human PTH-(1-34)] therapy. *J Rheumatol.* 2009 Aug;36(8):1835-7.
34. Cheung A, Seeman E. Teriparatide therapy for alendronate-associated osteonecrosis of the jaw. *N Engl J Med.* 2010 Dec 16;363(25):2473-4.
35. Bashutski JD, Eber RM, Kinney JS, Benavides E, Maitra S, Braun TM, Giannobile WV, McCauley LK. Teriparatide and osseous regeneration in the oral cavity. *N Engl J Med.* 2010 Dec 16;363(25):2396-405.
36. Badros A, Evangelos T, Goloubeva O, Meiller T, Kastritis E, Verrou E, Zervas K, Katodritou E, Streeten E, Baer MR, Dimopoulos MA. Long-term follow-up of multiple myeloma (MM) patients (pts) with osteonecrosis of the jaw (ONJ). *Blood (ASH Annual Meeting Abstracts).* 2007 Nov;110(11):3519.
37. Dimopoulos MA, Kastritis E, Bamia C, Melakopoulos I, Gika D, Roussou M, Migkou M, Eleutherakis-Papaikovou E, Bamias A. Decreased incidence of osteonecrosis of the jaw (ONJ) in patients with multiple myeloma (MM) treated with zoledronic acid (ZA) after application of preventive measures. *Blood (ASH Annual Meeting Abstracts).* 2007 Nov 16;110(11):3609.
38. Mehrotra B, Fantasia J, Ruggiero SL. Outcomes of bisphosphonate-related osteonecrosis of the jaw--Importance of staging and management guidelines: A large single institutional update. *J Clin Oncol.* 2008 May 20;26(15S):322.
39. Khosla S, Burr D, Cauley J, Dempster DW, Ebeling PR, Felsenberg D, Gagel RF, Gilsanz V, Guise T, Koka S, McCauley LK, McGowan J, McKee MD, Mohla S, Pendrys DG, Raisz LG, Ruggiero SL, Shafer DM, Shum L, Silverman SL, Van Poznak CH, Watts N, Woo SB, Shane E; American Society for Bone and Mineral Research. Bisphosphonate-associated osteo-

- necrosis of the jaw: report of a task force of the American Society for Bone and Mineral Research. *J Bone Miner Res.* 2007 Oct;22(10):1479-91.
40. Allen MR. Animal models of osteonecrosis of the jaw. *J Musculoskelet Neuronal Interact.* 2007 Oct-Dec;7(4):358-60.
41. Allen MR, Burr DB. The pathogenesis of bisphosphonate-related osteonecrosis of the jaw: so many hypotheses, so few data. *J Oral Maxillofac Surg.* 2009 May;67(5 Suppl):61-70.
42. Bi Y, Gao Y, Ehrchiou D, Cao C, Kikuri T, Le A, Shi S, Zhang L. Bisphosphonates cause osteonecrosis of the jaw-like disease in mice. *Am J Pathol.* 2010 Jul;177(1):280-90.
43. Kikuri T, Kim I, Yamaza T, Akiyama K, Zhang Q, Li Y, Chen C, Chen W, Wang S, Le AD, Shi S. Cell-based immunotherapy with mesenchymal stem cells cures bisphosphonate-related osteonecrosis of the jaw-like disease in mice. *J Bone Miner Res.* 2010 Jul;25(7):1668-79.
44. Kobayashi Y, Hiraga T, Ueda A, Wang L, Matsumoto-Nakano M, Hata K, Yatani H, Yoneda T. Zoledronic acid delays wound healing of the tooth extraction socket, inhibits oral epithelial cell migration, and promotes proliferation and adhesion to hydroxyapatite of oral bacteria, without causing osteonecrosis of the jaw, in mice. *J Bone Miner Metab.* 2010 Mar;28(2):165-75.
45. Gotcher JE, Jee WS. The progress of the periodontal syndrome in the rice rat. II. The effects of a diphosphonate on the periodontium. *J Periodontal Res.* 1981 Jul;16(4):441-55.
46. Sonis ST, Watkins BA, Lyng GD, Lerman MA, Anderson KC. Bony changes in the jaws of rats treated with zoledronic acid and dexamethasone before dental extractions mimic bisphosphonate-related osteonecrosis in cancer patients. *Oral Oncol.* 2009 Feb;45(2):164-72.
47. Hokugo A, Christensen R, Chung EM, Sung EC, Felsenfeld AL, Sayre JW, Garrett N, Adams JS, Nishimura I. Increased prevalence of bisphosphonate-related osteonecrosis of the jaw with vitamin D deficiency in rats. *J Bone Miner Res.* 2010 Jun;25(6):1337-49.
48. López-Jornet P, Camacho-Alonso F, Molina-Miñano F, Gómez-García F, Vicente-Ortega V. An experimental study of bisphosphonate-induced jaws osteonecrosis in Sprague-Dawley rats. *J Oral Pathol Med.* 2010 Oct;39(9):697-702.
49. Maahs MP, Azambuja AA, Campos MM, Salum FG, Cherubini K. Association between bisphosphonates and jaw osteonecrosis: A study in Wistar rats. *Head Neck.* 2011 Feb;33(2):199-207.
50. Biasotto M, Chiandussi S, Zacchigna S, Moimas S, Dore F, Pozzato G, Cavalli F, Zanconati F, Contardo L, Giacca M, Di Lenarda R. A novel animal model to study non-spontaneous bisphosphonates osteonecrosis of jaw. *J Oral Pathol Med.* 2010 May;39(5):390-6.
51. Senel FC, Duman MK, Muci E, Cankaya M, Pampu AA, Ersoz S, Gunhan O. Jaw bone changes in rats after treatment with zoledronate and pamidronate. *Oral Surg Oral Med Oral Pathol Oral Radiol Endod.* 2010 Mar;109(3):385-91.
52. Aguirre JI, Altman MK, Vanegas SM, Franz SE, Bassit AC, Wronski TJ. Effects of alendronate on bone healing after tooth extraction in rats. *Oral Dis.* 2010 Oct;16(7):674-85.
53. Allen MR, Burr DB. Mandible matrix necrosis in beagle dogs after 3 years of daily oral bisphosphonate treatment. *J Oral Maxillofac Surg.* 2008 May;66(5):987-94.
54. Burr DB, Allen MR. Mandibular necrosis in beagle dogs treated with

bisphosphonates. *Orthod Craniofac Res.* 2009 Aug;12(3):221-8.

Osteoporos Int. 2011 Feb;22(2):693-702.

55. Allen MR, Kubek DJ, Burr DB, Ruggiero SL, Chu TM. Compromised osseous healing of dental extraction sites in zoledronic acid-treated dogs.

56. Allen MR. Bisphosphonates and osteonecrosis of the jaw: moving from the bedside to the bench. *Cells Tissues Organs.* 2009;189(1-4):289-94.