

Ocular Inflammation Secondary to a Punctal Foreign Body

Dahlia R. Hirsch, MD; Eric R. Miller, OD (Contributors); Elisabeth J. Cohen, MD (Section Editor)

A 43-YEAR-OLD woman presented with a complaint of a red, swollen left eye. Pertinent history revealed a complaint of a foreign-body sensation after a haircut several days previously and no relief with use of self-prescribed gentamicin drops.

Gross examination revealed acute sectorial injection of the nasal bulbar conjunctiva in the left eye (**Figure 1**). Biomicroscopic examination revealed dilated conjunctival and episcleral vessels, with overlying conjunctival staining. Closer inspection showed a cylindrical foreign body with well-demarcated, blunt edges consistent with a fragment of fresh-cut hair protruding slightly from the superior punctum (**Figure 2**). The foreign body was removed, and the patient received a

combined antibiotic-steroid treatment. Subjective and objective improvement was noted in a matter of days.

COMMENT

This case underscores the importance of a careful history and examination of the entire eyelid when inflammations of the conjunctiva or episclera are diagnosed. A punctal foreign body as a causative factor of episcleritis can be easily overlooked.

Tear dynamics and the nature of the lacrimal drainage apparatus allow for punctal foreign bodies to occur easily. The average diameter of a human hair is approximately 0.08 mm, while the diameter of a punctum ranges from 0.3 to 0.5 mm. Tears produced by the lacri-

mal gland accumulate in the conjunctival fornices and the lacus lacrimalis by capillarity influence and by the blinking movements of the eyelids.¹ The puncta, which are kept in contact with the lacus lacrimalis, then drain the tears by capillarity to the canaliculi. One should always look for misdirected or dislodged cilia, or other less common foreign bodies such as in this case, and cut hair when there is localized nasal ocular inflammation mimicking episcleritis.

Selected from Arch Ophthalmol. 1996;114:625. Photo Essay.

REFERENCE

1. Snell RS, Lemp MA. The ocular appendages. In: *Clinical Anatomy of the Eye*. Boston, Mass: Blackwell Scientific Publications; 1989:109.

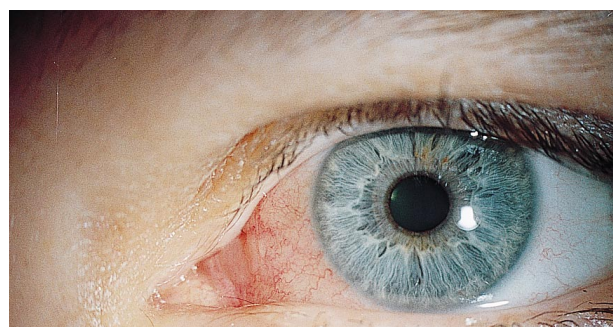

Figure 1. Sectorial conjunctival and episcleral injection nasally, left eye.

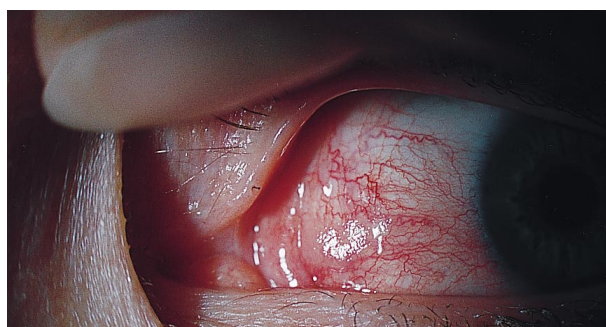


Figure 2. Recently cut human hair fragment protruding slightly from the superior punctum.