

# Sonographic evaluation of normal liver sizes of school children in south-east Nigeria

## ABSTRACT

**Introduction:** Race, ethnicity, and pathologies are some of the factors noted to affect liver sizes. Despite several reports on liver sizes of children from different countries, normative data on liver dimensions of children remain scanty in our population. The objective of this study was to establish the normal values of the liver in healthy school children in south-east Nigeria and to correlate them with body indices. **Materials and Methods:** A cross-sectional prospective study of 1315 children between the ages of 5 and 17 years was conducted. Data on age, sex, and anthropometric measurements of body size indicators such as WT, HT, body surface area (BSA), and body mass index were obtained. Sonographic measurements of the liver were done with the subjects in a supine position. Length was measured after clear visualization in the midclavicular line for the right lobe and mid-sagittal plane for the left lobe, from the highest to the lowest points of the liver. The liver span was measured from the most inferior aspect of the liver on the right diagonally to the most lateral point. Data were analyzed using SPSS version 15.0. **Results:** Age and all the body size indices correlated positively and significantly with the liver dimensions ( $P < 0.01$ ,  $P < 0.05$ ). BSA correlated best with the liver dimensions. The dimension of the right liver length correlated best with body habitus, followed by liver span. Liver sizes in males were larger than those in females. A regression model for prediction of liver dimension was computed. Baseline data for liver sizes with upper and lower limits at 5<sup>th</sup> and 95<sup>th</sup> percentiles, respectively, were determined. **Conclusion:** The liver sizes in Nigerian children were noted to be similar to those reported for Brazilians in South America, but larger than the values reported in China, Thai, Turkey, and Arab countries.

**Key words:** Anthropometry, biometry, body habitus, liver dimensions, liver span, Nigeria, nomogram, ultrasound

Salome N. Ezeofor<sup>1</sup>,  
Anyanwu G. Emeka<sup>2</sup>,  
Obikili N. Emmanuel<sup>1,2</sup>

Departments of <sup>1</sup>Radiation Medicine and <sup>2</sup>Anatomy, College of Medicine, Faculty of Medical Sciences, Enugu Campus, University of Nigeria, Enugu, Nigeria

### Address for correspondence:

Dr. Salome N. Ezeofor,  
Department of Radiation Medicine,  
College of Medicine,  
Faculty of Medical Sciences,  
Enugu Campus, University of  
Nigkmheria, Enugu, Nigeria.  
E-mail: ezeoforsalome@gmail.com

## INTRODUCTION

The liver is the largest organ in the body and also the largest gland. It has been estimated that between birth and adulthood, there is at least a 10-fold increase in liver mass.<sup>[1]</sup> The size of the liver has been reported to be affected by intrinsic liver disease and other systemic pathologies.<sup>[2-4]</sup> Several studies have been conducted on the establishment of normal liver sizes in adults,<sup>[2,5,6]</sup> newborns and infants,<sup>[7,8]</sup> and in pre-school and school children.<sup>[9-11]</sup>

Hepatomegaly is a frequent clinical finding in children and can be caused by intrinsic liver diseases or systemic disorders<sup>[4]</sup> which include malaria, inflammatory conditions like hepatitis, sickle cell anemia, tumors which can be primary or metastatic, infection from bacteria and parasites, poisons/toxins including ingestion of herbs and roots, acetaminophen, insecticide, and mushroom. Others include chronic cardiac failure, storage disorders, infiltrative disorders like leukemia, lymphoma, granulomas like tuberculosis,<sup>[12]</sup> autoimmune, non-alcoholic fatty liver, malnutrition like kwashiorkor, and trauma. Hepatomegaly is a condition that needs urgent further evaluation,<sup>[11]</sup> and ultrasound is usually the method of choice for screening, diagnostic, prognostic purposes, and in the follow-up after treatment because of its accuracy and easy accessibility, avoids use of ionizing radiation, and the technique is non-invasive and cheap. The importance of early detection of children with liver disease cannot be overemphasized because it is critical for optimal medical or surgical

### Access this article online

Quick Response Code:



Website:

www.bioanthrojournal.org

DOI:

10.4103/2315-7992.143406

intervention. A study done in Nigerian adults<sup>[13]</sup> showed that liver disease accounts for 7.9% of medical admissions and liver cirrhosis and primary liver cancer account for two-thirds of the liver diseases in hospitalized patients in a Nigerian hospital. The risk factors found in their study include the ingestion of common herbs and roots in our environment.

Primary liver cancer or hepatocellular carcinoma is the major cause of death by cancer worldwide, accounting for over half a million deaths per year.<sup>[14]</sup> It is the second leading cause of cancer-related deaths in the world.<sup>[15]</sup> Hence, there is an urgent need for the establishment of sets of normative values for our environment.

Various methods for assessment of liver sizes have been reported in the literature,<sup>[2,3,11,16-19]</sup> some of which include clinical evaluation by percussion, radiography and radionuclide studies, ultrasound, and computed tomography. The effectiveness of some of these methods has also been criticized.<sup>[20]</sup> Diagnostic imaging techniques have been reported to be much more superior to clinical examination in determining the size of the liver.<sup>[20,21]</sup> Clinical evaluation by percussion and palpation is flawed for its inability to provide precise liver dimensions. This procedure can only give gross estimation of sizes with very high tendencies for overestimation due to the pleural effusion or lung consolidation or underestimation due to tympany in the right upper abdomen.<sup>[22]</sup> Technetium liver scan has been criticized for its underestimation of the liver dimensions<sup>[23]</sup> and radiography and radionuclide studies for exposure of patients to ionizing radiation.<sup>[23,24]</sup> Computed tomography and Magnetic Resonance Imaging (MRI) have been noted to be expensive and uncommon in developing countries.<sup>[2]</sup> Ultrasound and Magnetic Resonance Imaging (MRI) have been made popular by its accuracy, affordability, and portability.

Race and ethnicity are some of the factors noted to affect liver dimensions.<sup>[5,9,16]</sup> Several studies have been done for establishing the liver dimensions of children in different parts of the world.<sup>[9,10,16,25-28]</sup> Despite the volume of normative and baseline data on liver dimensions for children in various parts of the world, there is paucity of information on the standard sizes of liver dimensions by ultrasound in most developing countries of Africa. This study was, therefore, designed to set baseline data for the liver dimensions using ultrasound for the Nigerian children and to determine their relationships with some body size indicators.

## MATERIALS AND METHODS

A cross-sectional prospective study of 1315 school-aged Nigerian children (5–17 years) in primary and secondary schools was carried out between the years 2009 and 2010.

The study surveyed participants from selected primary and secondary schools in the urban area of Enugu, one of the major towns in Nigeria. Sex, age, WT, and HT of the participants were measured. With WT measured in kilograms and HT in meters, BSA and body mass index (BMI) were calculated using the formula:

$$BSA = (WT \times HT/3600)^{1/2}$$

$$BMI = (HT^2/WT)$$

This study was approved by the ethics committee of the University of Nigeria teaching hospital, Enugu State, Nigeria. Informed consent, describing the purpose of the study, was obtained from all parents whose children were involved in the study. Only healthy-looking children were included in the study. Clinical exclusion criteria were fever, jaundice, macular or maculopapular rash, and lymphadenopathy. Imaging exclusion criterion was presence of parenchymal abnormal masses. Body WT and HT were noted to the nearest 0.1 kg and 0.1 cm, respectively, using a spring stadiometer scale.

### Sonographic examinations

Measurements of the liver dimensions were done by one of the radiologists. Scans were done with GE LOGIC 400CL manufactured by GE medical systems (United States of America) with a curvilinear probe of 3.5 MHz frequency. Two sequential measurements were obtained for each area and their mean was calculated; this is to minimize intraoperator variation and ensure greater accuracy and reliability of measurements. Measurements were taken in deep inspiration with the subjects holding their breath briefly. No preparation or sedation was used. The liver dimensions were measured using the methods described by Kratzer *et al.*<sup>[5]</sup> Measurements were made with the subjects lying in supine position with relaxed abdominal wall. The subjects' right hands were raised behind the head to help enlarge the intercostal spaces and the space between lower costal margin and the iliac crest, thereby creating better access to the liver. The longitudinal and diagonal axes of the liver were accessed. According to the method described by Kratzer *et al.*,<sup>[5]</sup> and Niederau *et al.*,<sup>[29]</sup> the liver size was measured in the midclavicular line for the right lobe (with the instrument running from the right hepatic dome to the inferior hepatic tip) and mid-sagittal plane for the left lobe, from the highest to the lowest point of the liver. The diagonal axis of the liver from its most inferior aspect on the right to the most lateral aspect on the left was measured as the liver span [Figures 1 and 2].

### Statistical methods

Data were compiled and analyzed using SPSS version 15.0 (SPSS Inc., Chicago, IL, USA). The relationships of all the dimensions of the liver with age, sex, WT, HT, BSA, and BMI were determined and regression models were established.

## RESULTS

Out of a total of 1350 participants sampled for this study, only the results of 1315 participants that met all the inclusion criteria were used. Of these, 633 (48.1%) were males and 682 (51.9%) were females. Distribution of subjects by

**Table 1: Distribution of liver dimensions with body size indices**

Age (years)	Frequency males	Frequency females
5.0	31	23.0
6.0	64	55.0
7.0	63	49.0
8.0	55	44.0
9.0	80	96.0
10.0	101	97.0
11.0	65	66.0
12.0	42	41.0
13.0	33	25.0
14.0	55.0	46.0
15.0	39.0	42.0
16.0	41.0	31.0
17.0	13.0	18.0

gender and age is summarized in Table 1. The subjects' age ranged from 5 to 17 years. Modal age group for both sexes was 10 years. The nomogram of liver dimensions by age is presented in Table 2. The mean with standard deviation and the 5<sup>th</sup> and 95<sup>th</sup> percentiles of the liver dimensions are presented in Table 2. In most age categories, males showed higher hepatic dimension than in the females. Pearson correlation matrix of the liver dimensions with age and body size indicators have been summarized in Table 3. Age and all body size indicators used correlated positively and significantly with all the liver dimensions ( $P < 0.01$ ). The right liver length is the liver dimension that correlated most with age and all the body size indices; this was followed by the liver span. Regression formula for predicting the various liver dimensions from age and different body size indicators is presented in Table 4.

## DISCUSSION

The importance of the knowledge of the normal range of values of various viscera in the identification of early pathological changes in the size of these organs can never be overemphasized. This study has set baseline data with ultrasound, which can be used as a comprehensive

**Table 2: Distribution of the various liver dimensions by age**

Sex	Age (years)	HT (cm)	WT (Kg)	BSA	RLL (cm)	Percentile		LLL (cm)	Percentile		LSPAN (cm)	Percentile	
						5 <sup>th</sup>	95 <sup>th</sup>		5 <sup>th</sup>	95 <sup>th</sup>		5 <sup>th</sup>	95 <sup>th</sup>
Females	5.0	113.5±5.2	19.6±2.3	0.8±0.1	10.2±1.2	8.4	12.2	7.6±1.3	5.0	9.6	10.0±1.7	6.8	12.2
	6.0	117.6±6.2	21.5±2.2	0.8±0.1	10.7±1.0	9.3	12.3	7.7±1.3	5.7	9.8	10.7±1.0	9.5	12.9
	7.0	125.3±5.7	24.6±3.0	0.9±0.1	11.0±0.9	9.3	12.3	7.9±1.2	5.7	9.8	11.1±1.0	9.5	12.9
	8.0	130.4±6.7	28.1±6.4	1.0±0.1	11.7±1.3	9.0	14.3	8.3±1.2	6.5	10.7	11.6±1.5	8.9	14.4
	9.0	137.0±6.5	31.7±6.0	1.1±0.1	12.0±1.1	10.3	14.0	8.5±1.2	6.4	10.3	11.8±1.3	9.8	13.6
	10.0	142.2±7.2	35.2±7.4	1.2±0.1	12.2±1.3	10.3	14.5	8.6±1.1	7.2	10.6	11.9±1.6	9.2	14.9
	11.0	145.9±8.6	37.7±6.9	1.2±0.1	12.4±1.2	10.6	14.6	8.8±1.1	6.8	10.4	12.1±1.6	9.4	14.4
	12.0	152.4±7.1	44.5±11.3	1.4±0.2	12.9±2.0	10.4	15.8	9.2±1.1	7.4	11.7	12.2±1.7	8.3	15.5
	13.0	155.1±7.4	45.7±13.1	1.4±0.2	13.2±1.6	10.2	16.0	9.3±1.2	7.0	11.8	12.3±1.4	9.7	15.4
	14.0	163.2±8.1	54.8±11.1	1.6±0.2	14.2±1.6	10.4	17.0	9.4±1.5	7.4	12.7	13.1±1.6	10.1	15.1
	15.0	164.5±6.8	56.1±9.1	1.6±0.1	14.3±1.1	13.0	16.5	9.7±1.2	7.4	11.7	13.5±1.4	10.3	15.6
	16.0	165.7±6.7	58.0±13.1	1.6±0.2	14.5±1.5	11.4	16.6	9.9±1.4	7.0	11.9	13.6±1.8	10.7	16.8
	17.0	166.7±1.2	58.5±7.8	1.7±0.1	14.6±1.2	12.9	16.7	10.1±1.6	6.1	12.4	13.7±1.2	12.1	16.0
	Males	5.0	113.6±5.4	21.0±2.5	0.8±0.1	10.7±1.2	8.2	13.1	7.7±1.1	5.8	9.4	10.7±1.2	9.2
6.0		118.2±5.3	22.5±3.1	0.9±0.1	10.9±1.0	9.4	13.0	7.8±1.2	9.0	13.3	11.0±1.3	9.0	13.3
7.0		125.7±4.7	25.1±3.1	0.9±0.1	11.5±2.2	9.5	13.6	8.1±1.2	6.2	10.3	11.2±0.9	9.5	13.0
8.0		130.2±4.7	27.6±4.5	1.0±0.1	11.8±1.4	9.7	14.6	8.3±1.1	6.6	10.1	11.6±1.2	9.6	14.0
9.0		136.3±6.0	31.1±4.7	1.1±0.1	12.2±1.3	10.3	14.3	8.6±1.1	6.6	10.3	12.1±1.3	10.0	14.3
10.0		141.3±5.3	33.5±5.5	1.2±0.1	12.2±1.2	10.0	14.5	8.6±1.2	6.7	10.5	12.1±1.3	10.0	14.7
11.0		144.3±6.9	35.4±5.8	1.2±0.1	12.6±1.2	10.5	14.6	8.9±1.0	7.3	10.9	12.2±1.8	9.7	14.9
12.0		146.3±8.7	39.4±9.2	1.3±0.2	12.9±1.4	11.0	16.5	9.2±1.4	6.6	12.0	12.3±1.7	9.4	14.9
13.0		154.2±7.3	43.4±9.7	1.4±0.2	13.2±1.3	11.1	15.3	9.4±1.5	6.2	12.7	12.3±1.7	9.5	16.4
14.0		162.5±6.1	54.6±11.5	1.6±0.2	14.3±2.0	11.1	16.2	9.5±1.6	6.5	12.0	13.1±1.4	10.9	15.2
15.0	166.9±5.3	58.1±12.2	1.6±0.3	14.5±1.2	12.8	16.6	9.7±1.4	6.7	11.4	13.4±1.1	11.7	15.5	
16.0	177.1±7.0	64.1±11.1	1.8±0.2	15.0±0.8	13.6	16.8	9.9±1.6	6.7	12.3	13.9±1.1	12.0	15.8	
17.0	177.0±6.5	62.2±8.1	1.8±0.1	15.0±1.1	13.2	16.6	9.9±1.5	6.1	13.6	14.4±1.3	12.5	16.6	

LLL=Left liver lobe, WT=Weight, HT=Height, LSPAN=Liver span, BSA=Body surface area

**Table 3: Pearson correlation matrix of liver dimensions with body size indices**

Parameters	Age (years)	HT (cm)	WT (Kg)	BSA	RLL (cm)	LLL (cm)	LSPAN (cm)
Age	1.0	0.881**	0.840**	0.882**	0.675**	0.453**	0.525**
HT	0.881**	1.0	0.875**	0.954**	0.683**	0.471**	0.549**
WT	0.840**	0.875**	1.0	0.978**	0.701**	0.452**	0.569**
RLL	0.675**	0.683**	0.701**	0.714**	1.0	0.523**	0.760**
LLL	0.453**	0.471**	0.452**	0.474**	0.523**	1.0	0.431**
LSPAN	0.525**	0.549**	0.569**	0.578**	0.760**	0.431**	1.0
BMI	0.061*	-0.197**	0.0	-0.062*	0.1	0.0	0.1
BSA	0.882**	0.954**	0.978**	1.0	0.714**	0.474**	0.578**

BMI=Body mass index; LLL=Left liver lobe, WT=Weight, HT=Height, LSPAN=Liver span, BSA=Body surface area; \*P<0.05, \*\*P<0.01

**Table 4: Regression formula for the various liver dimensions using the body size indicators**

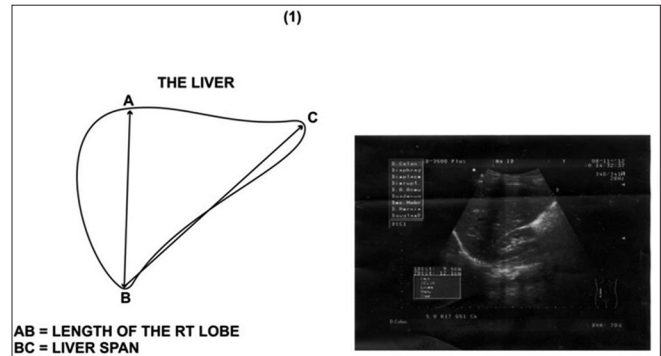
RLL	(7.12)+Age (0.12)+Ht (0.02)+WT (0.05)	<0.0001
LLL	(6.78)+Age (0.07)+Ht (0.001)+WT (0.03)	<0.0001
LSPAN	(8.01)+Age (0.04)+Ht (0.02)+WT (0.04)	<0.0001

[Age (years), RLL, LLL AND LSPAN (CM)], LLL=Left liver lobe, WT=Weight, HT=Height, LSPAN=Liver span, BSA=Body surface area

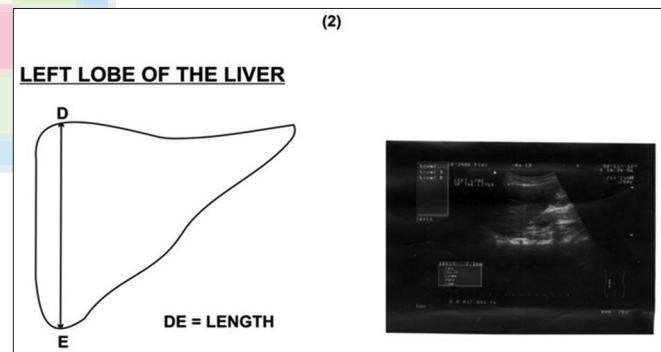
guide to normal liver dimensions for the Nigerian child within the age range of 5–17 years. Liver dimensions have been reported to vary with races and countries.<sup>[8,9,30,31]</sup> Dhingra *et al.*,<sup>[9]</sup> in a sonographic study of Indian children, showed larger liver size dimensions in their report when compared with a similar report by Jungthirapanich *et al.*,<sup>[8]</sup> for a sample of Thai children of the same age group. In another sonographic study by Weerakul *et al.*,<sup>[16]</sup> also on Thai children, they noted larger liver dimensions when compared with the report generated by El Mouzan *et al.*,<sup>[30]</sup> on Arab children of the same age group. Our study reports larger liver dimensions compared with studies on children of the same age group and body habitus in Turkey,<sup>[10]</sup> India,<sup>[9]</sup> and Brazil.<sup>[3]</sup> Liver sizes in this study were closer to the values reported for Americans and more than the European and Asian counterparts.

Several studies have established sexual dimorphism in liver dimensions where males showed larger liver sizes than females.<sup>[5,27,30,32]</sup> While there is no statistical significant difference between the various categories of males and females in this report, the male liver dimensions were larger than those of the females in most of the categories. This could be due to the fact that the majority of the sampled population was yet to pass through the changes associated with adolescent growth. An earlier study on the liver dimension of south-eastern Nigerians by Udoh *et al.*,<sup>[2]</sup> which combined both adolescent and adult populations, also reported significant difference in the liver sizes with larger dimensions in the male population.

Liver dimensions have been reported to correlate in various degrees with age, HT, WT, and BSA.<sup>[3,10,16,33]</sup> Of the three liver dimensions studied in this report, the right liver length correlated most with age and the various



**Figure 1:** Picture and diagram showing how the right liver lobe and liver span were measured



**Figure 2:** Picture and diagram showing how the left liver lobe was measured

body size indicators. This was followed by liver span and then left liver length. BSA correlated the most with the liver dimensions followed by WT. This observation is in agreement with earlier studies by Carpentieri *et al.*,<sup>[33]</sup> and Weerakul *et al.*,<sup>[16]</sup> Contrary to these reports, Dhingra *et al.*,<sup>[9]</sup> Konus *et al.*,<sup>[10]</sup> and Rocha *et al.*,<sup>[3]</sup> noted U to be the most correlating factor in their studies. Sarac *et al.*,<sup>[11]</sup> also did not find any significant correlation between liver dimensions with age, WT, HT, and BSA.

## CONCLUSION

We have been able to set baseline data for liver dimensions according to WT, HT, BSA, and age categories (5–17 years)



for the Nigerian population. This report also has set up the limits of these normal values for the categories. The relationship between the various liver dimensions with age and body habitus has also been studied. From the results of this report, a regression model for predicting the various liver dimensions has also been set up. Liver sizes in this study were observed to be larger in dimension when compared with those reported in studies from China, Thai, Turkey, and Arab countries.

## REFERENCES

- Balistreri WF. Manifestation of liver disease. In: Behrman RE, Kliegman RM, Jenson HB, editors. *Nelson's Textbook of Pediatrics*. 16<sup>th</sup> ed. Philadelphia: WB Saunders; 2000. p. 1198.
- Udoh BE, Eze JC, Chiegwu HU. Sonographic assessment of liver sizes in healthy south east Nigerians. *Am J Sci Res* 2011;14:88-92.
- Rocha SM, Ferrer AP, Oliveira IR, Widman A, Chammas MC, Oliveira LA, *et al.* Sonographic determination of liver size in healthy newborns, infants and children under 7 years of age. *Radiol Bras* 2009;42:7-13.
- Walker WA, Mathis RK. Hepatomegaly. An approach to differential diagnosis. *Pediatr Clin North Am* 1975;22:929-42.
- Kratzer W, Fritz V, Mason RA, Haenle MM, Kaechele V; Roemerstein Study Group. Factors affecting liver sizes: A sonographic survey of 2080 subjects. *J Ultrasound Med* 2003;22:1155-61.
- Kwo PY, Ramchandani VA, O'Connor S, Amann D, Carr LG, Sandrasegaran K, *et al.* Gender differences in alcohol metabolism: Relationship to liver volume and effect of adjusting for body mass. *Gastroenterology* 1998;115:1552-7.
- Wladimiroff JW, Sekeris A. Ultrasonic assessment of liver size in the newborn. *J Clin Ultrasound* 1977;5:316-20.
- Jungthirapanich J, Kaewtubtim J, Poovorawan Y. A new reference line for measuring the liver size in healthy newborns. *J Med Assoc Thai* 1998; 81:938-43.
- Dhingra B, Sharma S, Mishra D, Kumari R, Pandey RM, Aggarwal S. Normal values of liver and spleen size by ultrasonography in Indian children. *Indian Pediatr* 2010;47:487-92.
- Konuş OL, Ozdemir A, Akkaya A, Erbaş G, Celik H, Işık S. Normal liver, spleen, and kidney dimensions in neonates, infants, and children: Evaluation with sonography. *AJR Am J Roentgenol* 1998;171:1693-8.
- Sarac K, Kutlu R, Yakinci C, Durmaz Y, Baysal T, Özgen Ü. Sonographic evaluation of liver and spleen size in school-age children. *Turk J Med Sci* 2000;30:187-90.
- D'Agata ID, Balistreri WF. Evaluation of liver disease in the paediatric patient. *Pediatr Rev* 1999;20:376-88.
- Nwokediuko SC, Osuala PC, Uduma UV, Alaneme AK, Onwuka CC, Mesigo C. Pattern of liver disease admissions in a Nigerian tertiary hospital. *Niger J Clin Pract* 2013;16:339-42.
- Parkin DM, Bray FI, Devesa SS. Cancer burden in the year 2000: The global picture. *Eur J Cancer* 2001;37(Suppl 8):S4-66.
- Jermal A, Bray F, Centre MM, Ferlay J, Ward E, Forman D. Global cancer statistics. *CA Cancer J Clin* 2011;61:69-90.
- Weerakul J. Physical and ultrasonographic estimation of liver size in healthy Thai children under two years old. *Asian Biomed (Res Rev News)* 2011;5:403-6.
- Henderson JM, Heymsfield SB, Horowitz J, Kutner MH. Measurement of liver and spleen volume by computed tomography. Assessment of reproducibility and changes found following a selective distal splenorenal shunt. *Radiology* 1981;141:525-7.
- Dittrich M, Milde S, Dinkel E, Baumann W, Weitzel D. Sonographic biometry of liver and spleen size in childhood. *Pediatr Radiol* 1983;13:206-11.
- Markisz JA, Treves ST, Davis RT. Normal hepatic and splenic size in children: Scintigraphic determination. *Pediatr Radiol* 1987;17:273-6.
- Zoli M, Magalotti D, Grimaldi M, Gueli C, Marchesini G, Pisi E. Physical examination of the liver: Is it still worth it? *Am J Gastroenterol* 1995;90:1428-32.
- Sapira JD, Williamson DL. How big is the normal liver? *Arch Intern Med* 1979;139:971-3.
- Seidel HM, Ball JW, Dains JE, Benedict GW. *Mosby's Guide to Physical Examination*. 6<sup>th</sup> ed. St Louis: Mosby; 2006. p. 521-78.
- Castell DO, Frank BB. Abdominal examination: Role of percussion and auscultation. *Postgrad Med* 1977;62:133.
- Hendee WR, O'Connor MK. Radiation risks from medical imaging: Separating fact from fancy. *Radiology* 2012;264:312-21.
- Brenner DJ, Shuryak I, Einstein AJ. Impact of reduced patient life expectancy on potential cancer risks from radiologic imaging. *Radiology* 2011;261:193-8.
- Joshi R, Singh A, Jajoo N, Pai M, Kalantri SP. Accuracy and reliability of palpation and percussion for detecting hepatomegaly: A rural hospital-based study. *Indian J Gastroenterol* 2004;23:171-4.
- Lawson EE, Grand RJ, Neff RK, Cohen LF. Clinical estimation of liver span in infants and children. *Am J Dis Child* 1978;132:474-6.
- Kaya S, Ramazan K, Cengiz Y, Yasar D, Taner B, Unsal O. Sonographic evaluation of liver and spleen size in school-age children. *Turk J Med Sci* 2000;30:187-90.
- Niederer C, Sonnenberg A, Müller JE, Erckenbrecht JF, Scholten T, Fritsch WP. Sonographic measurements of the normal liver, spleen, pancreas, and portal vein. *Radiology* 1983;149:537-40.
- El Mouzan MI, Al Salloum AA, Al Herbish AS, Al Qurachi MM, Al Omar AA. Liver size in Saudi children and adolescents. *Saudi J Gastroenterol* 2009;15:35-8.
- Chen CM, Wang JJ. Clinical and sonographic assessment of liver size in normal Chinese neonates. *Acta Paediatr* 1993;82:345-7.
- Castell DO, O'Brien KD, Muench H, Chalmers TC. Estimation of liver size by percussion in normal individuals. *Ann Intern Med* 1969;70:1183-9.
- Carpentieri U, Gustavson LP, Leach TM, Bunce H 3rd. Liver size in normal infants and children. *South Med J* 1977;70:1096-7.

**How to cite this article:** Ezeofor SN, Emeka AG, Emmanuel ON. Sonographic evaluation of normal liver sizes of school children in south-east Nigeria. *Ann Bioanthropol* 2014;2:29-33.

**Source of Support:** Nil, **Conflict of Interest:** None declared.