

Idiopathic Retroperitoneal Hematoma

Sherif Monib¹, Andrew Ritchie², Ezzuldin Thabet³

¹⁻³General Surgery Department Mouwasat Hospital Qatif,

²Watford General Hospital, West Hertfordshire Trust,
Hertfordshire, UK

INTRODUCTION

The retroperitoneum is a large space bounded anteriorly by the posterior parietal peritoneum, posteriorly by the transversalis fascia, and superiorly by the diaphragm. Inferiorly, it extends to the level of the pelvic brim.

Idiopathic retroperitoneal hematoma is a rare but potentially life-threatening pathological cause of an acute surgical abdomen. In the early stages it typically presents as generalized abdominal pain, nausea, anorexia. The symptoms and signs of hypovolemic shock normally present late.

As management of idiopathic retroperitoneal hematoma is usually conservative, early diagnosis can save the patient an unnecessary exploration. This will improve morbidity and mortality in this group of patients.

CASE REPORT

We present the case of a 23-year-old female seen in the Accident and Emergency Department with a sudden onset of acute abdominal pain. The pain was described as dull and aching in nature, sited diffusely over the entire abdomen before localizing to the right iliac fossa. The pain had increased in severity over the preceding 12 hours. There was no associated nausea, vomiting or anorexia. Her medical history included no history

ABSTRACT

Idiopathic retroperitoneal hematoma is a rare, but potentially life threatening cause of an acute surgical abdomen. Initially diagnosis may be overlooked, leading to unnecessary exploration, which may have implications for prognosis of the patient. An enhanced Computer Tomography (CT) scan of the abdomen is the principle method of diagnosis. However, as in our case, laparoscopic management of the acute abdomen can play a vital role in this group of patients. Importantly, early diagnosis and vigilant conservative management can improve the outcome in idiopathic retroperitoneal hematoma.

Key words: Abdominal apoplexy, acute abdomen, retroperitoneal hematoma, Shock

of trauma or anticoagulation. She had undergone an uncomplicated vaginal delivery ten days prior to presentation with no obstetric concerns.

On physical examination the patient appeared generally well. She was afebrile and her observations were stable with the exception of borderline tachycardia at 92 beats per minute. On abdominal examination she had a soft abdomen with only mild tenderness in the right iliac fossa and suprapubic regions. There was no rebound tenderness and Rovsing, Obturator, and Psoas signs were all negative. Both renal angles were mildly tender. Digital, rectal, and vaginal examinations were normal.

Initial Laboratory findings revealed: Hb 13 g/dl, PCV 38.8%, WCC 6.1×10^3 , CRP 62 mg/l Hb A 61.26, Hb A2 0.72%, Hbs 38.02%, Ret count 1.03%, INR 0.89, and Urine dipstick testing was unremarkable.

As for imaging modalities; a preoperative abdominopelvic ultrasound scan (USS) demonstrated no abnormalities, with the exception of minimal free fluid in the peritoneal cavity.

Based on a history of nausea and generalized abdominal pain localizing to the right iliac fossa, our provisional diagnosis was early acute appendicitis. The Alvarado score, along with the USS findings, supported this provisional diagnosis.^[1]

Access this article online

Quick Response Code:



Website:

www.jstcr.org

DOI:

10.4103/2006-8808.78475

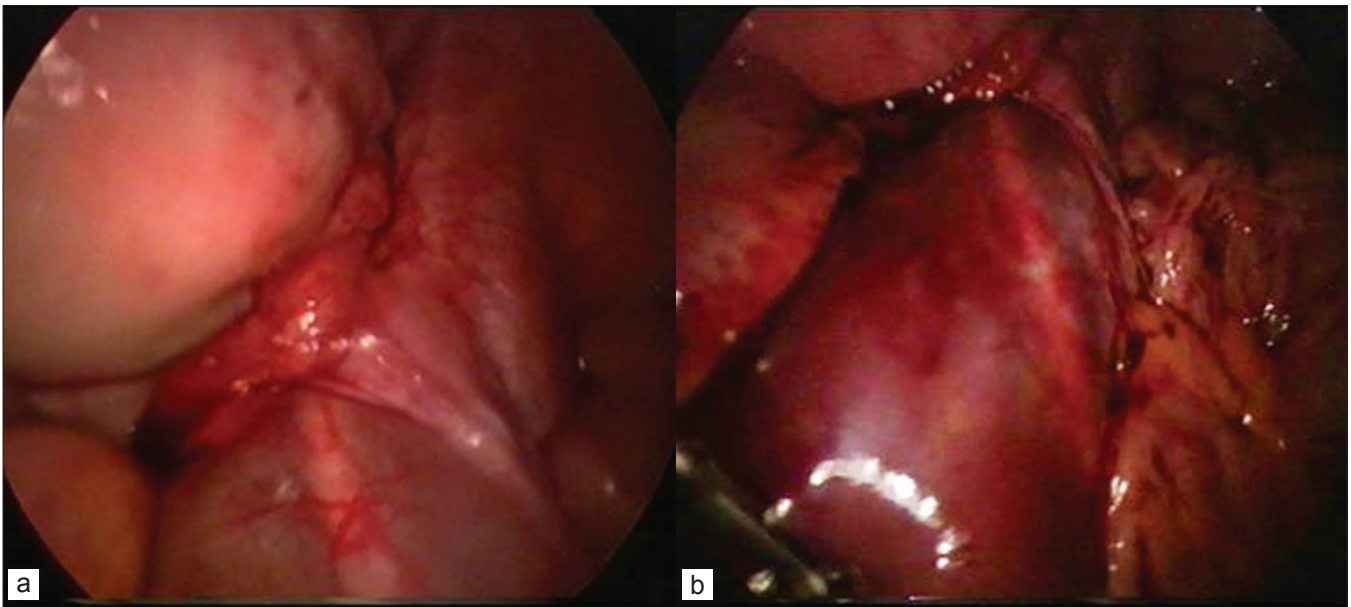
Address for correspondence: Dr. Sherif Monib,
Watford General Hospital, WD18 0HB, West Hertfordshire
Trust, Hertfordshire, UK. E-mail: sherifmonib@gmail.com

At this stage we commenced intravenous paracetamol, subcutaneous enoxaparin, compression stockings, and intravenous normal saline.

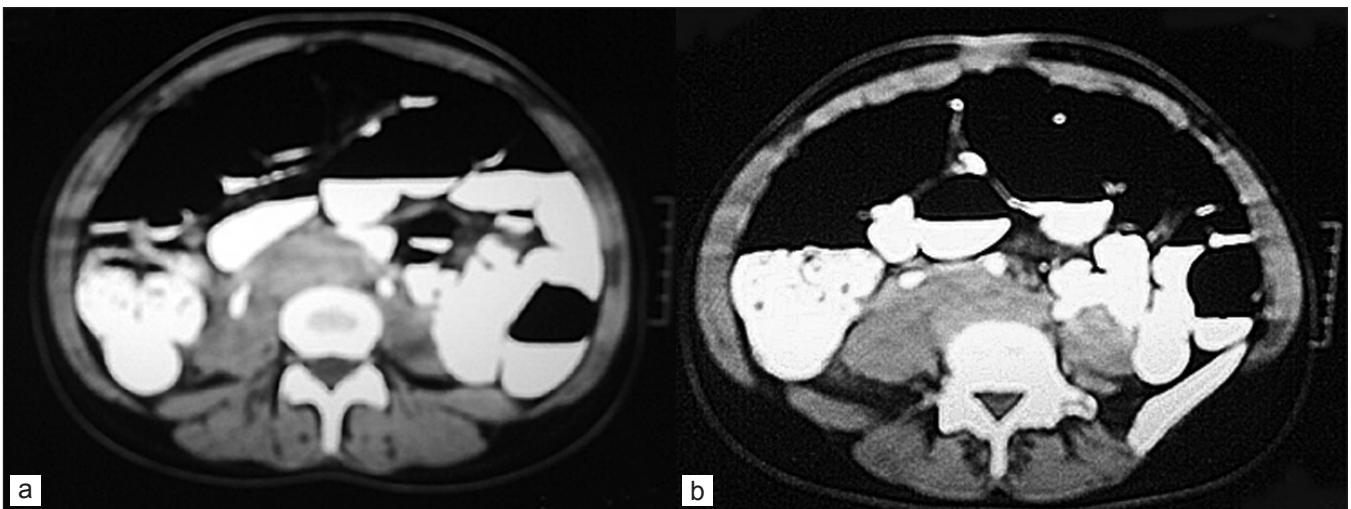
The patient went on to have a diagnostic laparoscopy, which revealed a normal appendix, and adnexia, but minimal hemorrhagic peritoneal fluid and a retroperitoneal hematoma extending from the pelvis up to the duodenum [Figure 1a and b].

Keeping in mind the patient's young age, the fact she was hemodynamically stable, and the laparoscopic findings of a confined and nonpulsating hematoma, we decided to undertake conservative measures.

Postoperatively she was observed in the Intensive Therapy Unit (ITU) for 48 hours with the team prepared for laparotomy if necessary. Postoperatively the enoxaparin was withheld for 48 hours and she received three doses of intravenous Co-amoxiclav. An enhanced CT scan of the abdomen demonstrated the retroperitoneal hematoma surrounding the Aorta and Inferior Vena Cava, starting below the lower pole of the kidneys extending down past the aortic bifurcation, with lateral extension over both the psoas muscles [Figure 2a and b]. On the fourth postoperative day our patient was able to tolerate oral clear fluids and she was discharged the next day. A follow-up abdominal CT scan of the abdomen, carried out two weeks post laparoscopy, revealed gradual regression of the



Figures 1 (a-b): Laparoscopic view of the retroperitoneal hematoma



Figures 2 (a-b): Postoperative CT scan of the abdomen

dimensions of the hematoma without specific surgical or therapeutic intervention.

DISCUSSION

There are several well-recognized causes of retroperitoneal hematoma, including ruptured aortic aneurysm, traumatic vascular injury, retroperitoneal neoplasms, and coagulopathy.^[2] In addition, there are documented reports implicating low molecular weight heparin as a potential cause.^[3] However, as with our patient, there are rare idiopathic cases of spontaneous rupture of branches of the splanchnic vessels.

Maurice Barber first described idiopathic retroperitoneal hematoma, known originally as abdominal apoplexy, in 1909.^[4,5]

Detecting a retroperitoneal hematoma in the early stages may not be possible, as clinically assessing the retroperitoneum can be challenging, particularly in obese patients or in those with a large volume of bowel gas.

Idiopathic retroperitoneal hematoma may present symptomatically in the form of acute abdominal pain, nausea, and anorexia. While on physical examination the patient may have a tender abdomen and hypovolemic shock.^[6]

As idiopathic retroperitoneal hematoma is a rare entity, it is not always included in the differential diagnosis of acute abdominal pain. Missing this diagnosis can lead to unnecessary laparotomies with accompanied implications for morbidity and mortality.

To avoid such situations idiopathic retroperitoneal hematoma must be considered when dealing with the acute abdomen. Enhanced CT scan of the abdomen

is the principle method of diagnosis and will also delineate the site and size as well as rule out other causes of retroperitoneal hematoma.^[6] In our case, diagnostic laparoscopy was the key to successfully diagnosing a retroperitoneal hematoma, while excluding intraperitoneal pathology. Therefore, laparoscopy had an important role in this patient's subsequent management.

CONCLUSION

While idiopathic retroperitoneal hematoma is rare, it should nevertheless be included in the differential diagnosis for patients presenting with acute abdominal pain. An enhanced CT scan of the abdomen is the principle method of diagnosis and will also delineate the site and size as well as rule out specific causes of retroperitoneal hematoma. As in our case, laparoscopy can have a valid role in the management and will avoid unnecessary laparotomies. Importantly, early diagnosis and vigilant conservative management can improve the outcome in idiopathic retroperitoneal hematoma.

REFERENCES

1. Alvarado A. A practical score for the early diagnosis of acute appendicitis. *Ann Emerg Med* 1986;15:557-64.
2. Al-Khulaiwi A, Razaak FA, El Shair A, Bamehriz F. Idiopathic retroperitoneal hematoma. *Ann Saudi Med* 2000;20:270-1.
3. Ernits M, Mohan PS, Fares LG 2nd, Hardy H 3rd. A retroperitoneal bleed induced by enoxaparin therapy. *Am Surg* 2005;71:430-3.
4. Barber MC. Intra-abdominal Haemorrhage Associated with Labour. *Br Med J* 1909;2:203-4.
5. Nair HT, Dolphin JM. Idiopathic retroperitoneal haemorrhage. *Clin Pract* 1990;44:733-4.
6. Stewart BT, McLaughlin SJ, Thompson GA. Spontaneous retroperitoneal haemorrhage: a general surgeon's perspective. *Aust N Z J Surg* 1998;68:371-3.

How to cite this article: Monib S, Ritchie A, Thabet E. Idiopathic retroperitoneal hematoma. *J Surg Tech Case Report* 2011;3:49-51.

Source of Support: Nil, **Conflict of Interest:** None declared.